



„LUCIAN BLAGA”  
UNIVERSITY OF  
SIBIU  
„VICTOR PAPILIAN”  
FACULTY OF MEDICINE

# Laparoscopic surgery for hepatic hydatid cyst -summary-

Scientific coordinator:  
Prof. Adriana Stănilă PhD

PhD candidate:  
Dr. Alexandru-Dan Sabău

Sibiu, 2011

## **General part**

### **Importance of the theme**

Hydatidosis is a zoonosis whose main cause is *Taenia echinococcus*, especially *granulosus* and *multilocularis* forms. This disease is still very widespread, the larval stage causing disease in humans, sheep, goat, horse, buffalo and camel.

Worldwide disease spread, but mainly in endemic areas (Mediterranean basin, New Zealand, Australia, North Africa, Eastern Europe, Northern Mediterranean, South America) (27), justifies the approach of the theme in terms of radical visa treatment (surgery) with minimal negative impact on the patient's body.

Globalization, including recent years' migration and tourism, made the problem to be approached by the countries that typically had a low incidence of the disease or was considered eradicated or (Western Europe, United States of America), or by moving trained surgeons outside the areas with hydatid pathology in endemic areas (25, 120).

In Romania, the incidence was of 5.6 per 100,000 inhabitants / year (Gh. Lupaşcu 1953-1963, 10 times quoted) and between 1991-1995, 1000 new cases per year, (I. Gherman 10 times quoted) with top points in areas where intensive shepherding was practiced (Sibiu, Dobrogea).

Disease behaviour, with slow but steady growth, with the possibility of metastasis at the level of the main focus almost in every organ, the large frequency of the hepatic localizations, the possibility of extremely powerful complications, the impossibility of treating this affection through conservative or semi-conservative methods, represent the motivation for choosing this study topic.

The need for studying this topic also consists of the following requirements of the hydatid cyst surgery:


1. Secured cystic decontamination;
2. External and internal environment cyst complex isolation;
3. Stabilization of the cyst - aspiration system – external environment complex;
4. Fluidisation of the cystic content;
5. Facilitation of the “complete” cystic evacuation in secured extra-peritoneal closed system;
6. Visualization of the spheroid plague with the sanctioning of the vesicular connections or rests;
7. Treatment of the peri-chyst according to the acquisitions of the open surgery;

8. Chemotherapy treatment of the disease.

## History

The first mentions of the hydatid disease date since Ancient Egypt, in the year 1534 BC, in Ebers' papyrus, a document dating from the time of Pharaoh Den, the first dynasty, and discovered in 1875, a document that measures 20 feet long. Talmud, a compilation of erudite opinions, marks the medical world, mentioning among other things, the hepatic hydatid disease, as well.(10.11)

The description of "liver full of water" belongs to Hippocrates of Kos (460-375 BC) (10, 11), who also mentioned the hydatid peritonitis after the perforation of hydatid cyst, followed by death. Other descriptions of the hydatid disease belong to Aretaeus of Cappadocia (AD 9-79) and Claudius Galenus (129-199 AD), but the origin of the disease remains unknown at the time.



Hippocrates of Kos



Aretaeus of Cappadocia

During the Middle Ages, important progress have been made in hydatid liver disease which was completed in 1670 by Francesco Redi (1626-1697), who guessed the animal origin of the disease by Edward Tyson (1650-1708), as well, who issued the hypothesis of parasitary origin.(11)

The first evidence of parasitary origin is brought in 1781 by Pallas, followed in 1782 by Geotze, both of them highlighting protoscoleces at microscopes, in cysts belonging to animals.(28)

The adult parasite was revealed in 1801 by Rudolph, in dog intestine, classifying it in *Echinococcus* genus, while in 1821, Bremser highlighted protoscoleces in hydatid cysts belonging to humans.

In the mid-nineteenth century, in 1853, von Siebold, following the theory of “alternating generations” and the law of “parasitic worms transmigration” issued by van Beneden in 1847, succeeded in proving by experiments, the first stage of the evolutive cycle of the parasite, making a dog to ingest hydatid cysts, obtaining the adult form of the parasite in the dog’s intestine, parasite whom he calls *Taenia Echinococcus*. Echinococic great cycle data were completed and finalized in 1882 by Leuckart and Heubner.(11, 62)

Small parasitic cycle data originally issued by Hunter in 1786 based on clinical observations complemented by Budd (1857) and Bright (1861), the last of them recognizing the danger of cyst puncturing or opening. In 1871, Finsen communicated a study of 11 post-operative recurrence cases following surgical insemination, confirming the thesis of Budd and Bright.(11, 28) These observations were demonstrated in 1897 by Alexinski, who experimentally reproduced multiple peritoneal hydatid cysts from daughter vesicles, brood capsules and protoscoleces. In 1901, Felix Devecare completed the knowledge about hydatidosis by studying and communicating the different aspects of parasite biology: vesicular degeneration, hydatid anaphylaxis, their scolex migration, “direct conversion of scoleces in echinococic vesicles” intuiting and demonstrating the first measures for the annihilation of the secluded but alive parasite, by using formalin as scolicide agent.

In the early twentieth century, Volkmann and Deve demonstrated the possibility of the occurrence of secondary echinococcosis and accomplished extensive studies in parasite biology and allergic reactions in hydatid disease.(28)

In the coming years, there have been a few attempts in order to establish biological diagnostic methods based on hydatid anaphylaxis study, research in this regard being made by Portier and Richet (1902), Gheradini and Joest (1906), Fleig and Lisbonne (1907).(11) However, the person who manages a first method of certain immunologic diagnosis is Casoni in 1912, by the intradermoreaction that bears his name. One year later, Weinberg and Pârvu brought a new immunological diagnostic method, the complement fixation reaction (RFC).

In the diagnosis of hepatic hydatid cyst, another discovery that has left its mark was the use of radiodiagnosis, which actually represented the first step in modern imaging. Among the imaging methods, ultrasound has been and remains one of the methods with the widest applicability for hepatic hydatid cyst, the one that enabled the diagnosis of this condition in uncomplicated stages and having an important role in the minimally invasive therapy.

Echography was discovered around 1940, by George Ludwig, Douglas Howry and John Wild who independently demonstrated that the ultrasounds transmitted in the body are sent back to the same transducer, reflected at the level of the interfaces of tissues with different densities.(28, 91, 106)

The treatment of this condition represented another area of attempts, solutions and discoveries, passing through different stages; the medical treatment, with multiple versions, were not offering the expected results, the only solution that remained were the surgical ones, which began to be imposed starting with the second half of the nineteenth century, the limits being imposed by the inefficient or even absent methods for asepsis and anti-asepsis, reason for which three methods remained sovereign: simple evacuatory puncture, puncture followed by injecting a parasitic substance (copper sulphate, fenic acid, iodoform, iodine tincture, mercury salts sublimate, bile, formalin) and two-stroke marsupialization (cyst opening and securing of the abdominal wall). Simple puncture, risky in the “blind” versions was updated in 1985 by Mueller under ultrasound guidance, reaching afterwards the modern versions (PAI, Double PAIR).(50, 156)

The year 1879 marked the transition to the modern treatment of hydatid hepatic cyst by practicing a surgery in a time when the protection of the peritoneal cavity was done by suturing the peri-cyst to the wall (marsupialization), exposed by Kirschner, later known under the name of Lindeman-Landau surgery.

The surgical interventions that reinsert the cyst resected and sutured in the abdominal cavity (Knowsley Thornton), a method taken over and used by other surgeons of the time: Bond, Posadas, Billroth, Eduard Quenu;(110) the technique was abandoned and then updated by Stoica, Sabau in open surgery, then in miniinvasive surgical approaches.

Preventing parasite and secondary echinococcosis dissemination represented another problem to be solved, and in 1900, Felix Franke used formalin for the first time in liver hydatid cyst surgery, the method being afterwards spread by Deve and Rouen in 1901 and the first intrasurgery formolization was performed by Eduard Quenu in the year 1902.

In 1896, it took place the first surgical intervention that probably remained the most commonly used to treat hepatic hydatid cyst: partial peri-cystic resection imagined by Mabitt, Russell and Lagrot and known as Mabitt-Lagrot. Total cystic-pericystectomy with open cyst (Pozzi – 1887) and with closed cyst (the ideal cystic-pericystectomy Napalkoff – 1904) were followed by hepatectomies adjusted for hydatid cyst (left hepatectomy accomplished by a team of surgeons made up of Seneque, Roux, Chatelin si Huguenard).(106, 125)

The first mentions of hepatic hydatid cyst in our country occurred in the late nineteenth century (Severeanu, Toma Ionescu, Leonte), then by Iacobov (325 hydatid cysts, of which 48%, with hepatic localization), Pop, Muresan, Podeanu, while the parasite experts, Leon and Ciurea, showed particular aspects of the cyst.(10, 11, 18)

After World War II, research gets large proportions; authors such as Hortolomei, Jianu Butureanu, Juvara, Carpinisan, Fagarasanu, Teodorescu, Burlui, Stoica, Setlacec present statistics showing the large number of cases, the clinical diversity, as well as the technique of surgical interventions.

In the year 1957, the first symposium on “cyst hidatic” was held in Constanta, organized by Dr. D.Teodorescu, which brings important surgical indications, while in 1958, I.Juvara published a monography on lung hydatid cyst.

Other works of great importance in the study of hydatid cyst are that of I. Fagarasanu 1967, “Hydatidosis” published in 1968 by Prof. Dr. Gh.Lupascu and Dr. D.Panaitescu, “Liver hydatid cyst surgery” written by Burlui and Monica Rosca in 1977 and Chapter 13 of “Liver surgery”, the author being Prof. Dr. Dan Sabau, edited by Irinel Popescu. Between 1956-1966, a programme to prevent and fight against larval cestoses (Olteanu et al.) was developed and put into practice, which brought remarkable results.

In 1990, the Romanian Association of Parasitology was founded, which in time, became a member of various international associations.

## **Special part**

### **Description of the devices**

Laparoscopic surgical treatment of the hepatic hydatid cyst was performed using standard laparoscopic instruments and equipment, additionally using the optical telescope with 12-mm working channel and the original laparoscopic instrument, consisting of a sealed self-fixing device for the aspiration of the hepatic hydatid cyst (OSIM 120809/30.04.2008 patent - Univ. Dr. Dan Sabau) with further evolution and a device for the fragmentation of the hydatid cyst content (OSIM Patent no. 120810/30.04.2008 – Prof. Univ. Dr. Dan Sabau).

### **Procedure and fluidisation device of the hepatic hydatid cyst content (128)**

The device for the fluidisation of the content of the hydatid cyst and ovarian cyst is an instrument patented by OSIM (OSIM patent no. 120810/30.04.2008 – Prof. Univ. Dr. Dan Sabau), which can be used, both in classic open miniinvasive surgery, but especially in laparoscopic surgery, where the need for extracting the cystic content by aspiration through 20mm orifices brought about the need for the fragmentation of its content (daughter vesicles and brood membrane), which is voluminous most of the times and with a structure less comprehensible, which may block the evacuation path.

Also, another requirement is the length of the laparoscopic instruments, which significantly exceeds that of the instruments used in open surgery.

Hepatic hydatid cyst device consists of an independently powered gear motor set that drives a rotating blade rotating in its turn a rod terminal. The transmission of the rotation movement towards the rod is made through an elastic sleeve which allows the inclination of the rotation rod at angles of up to 90°. In the opposite part of the elastic sleeve that connects

the rod to the gear motor, there is a wide hinged flag, which during the rotation movement of the rod departs from it at an angle of 90° under the action of the centrifugal force.

The folding palette facilitates its introduction through the trocar used in laparoscopic surgery inside the hydatid cyst, thus accomplishing the homogenization of its content through fragmentation and fluidity.

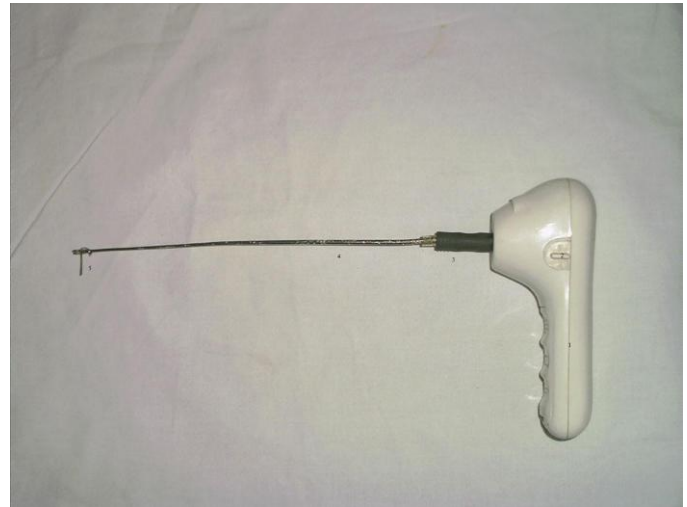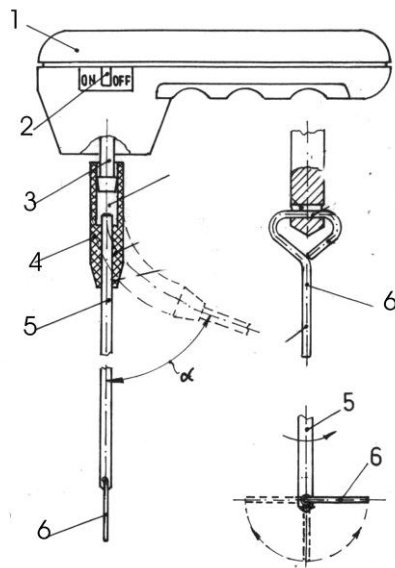
As described above, the device for the fluidisation of the contents of hydatid cyst consists of a manually operated gear motor set, preferably powered by batteries for increased mobility, but which can also be powered from the network and equipped with a switch that being acted, it brings about the rotation of an output shaft. The output shaft is connected to a flexible rubber sleeve, which is a joint that can reach an angle of 90° as against the motor gear assembly, but capable to transmit the necessary couple. This sleeve is connected to a stainless steel rod with a diameter of 2.5 and 3.5 mm and a length of 230-300 mm. Where necessary, the device can be equipped with a set of more such interchangeable rods, with different lengths but with the same diameter, in order to be coupled with the elastic sleeve.

At the opposite end of the elastic sleeve, the rod is provided with a transverse hole for the equipment of the folding palette, made up of stainless steel round wire with a diameter between 1.5 and 2 mm. The folding palette consists of a straight segment which continues with a triangular ring and the opposite side of the straight segment is inserted into the orifice the rod of the device is provided with, being able to oscillate freely around an axis.

The gear motor draws the rod with a rotation speed of 500 – 1000 rot/min, what makes that the folding palette to depart from the axis under the action of the centrifugal force, up to an angle of 90°, thus accomplishing the fragmentation of the cystic content.

In order to obtain the best results, the device for the fluidisation of the hydatid cyst content is preferably used together with the device for the aspiration of the hepatic hydatid cyst, described below:





Device for the fluidisation of the hepatic hydatid cyst (128)

- 1-electric gear motor; 2-commutator;
- 3. coupling for the elastic sleeve
- 4- elastic sleeve; 5-rotating rod; 6-palette

- 1 – gear motor assembly 2. switch
- 3. elastic sleeve 4. metal rod
- 5 – folding palette

## Device for the aspiration of the hepatic hydatid or ovarian cyst (127)

The device for the aspiration of the hepatic hydatid or ovarian cyst solves the problem of a certain and stable approach of the hepatic hydatid cyst, surmounting the problems of other devices that will be described below:

The device for the aspiration of the hepatic hydatid cyst is made up of certain elements:

- peripheral aspiration tube (of security), with transparent body (preferably) connected to the aspiration source;

- anchoring hooks;
- central tube connected to the parasitic aspiration source.

The device for the aspiration of the hepatic hydatid cyst aspiration is provided inside its body with a vacuum (sucking) and mechanical (hooks) anchor assembly whose distal end exceeds the end of the body with a length of 5-8 mm, inside the anchor assembly being introduced, coaxially, an inner trocar that is blocked in the peri-cyst. Through the inside of the trocar, a central tube connected to the aspiration source may be inserted, or other instruments (forceps, telescope). The device is equipped with two suction coaxial channels, the first of them being necessary for cyst aspiration and for the evacuation of the fluid leak, while the second is made up of a central tube, which provides the evacuation of the cyst content through aspiration.

The body of the device is made of transparent plastic, one end being provided with a cylindrical rake where a socket of the anchoring assembly enters and is fixed upon. The escaping continues with a conical boring where a thickening of the inner trocar is fixed by self-blocking, providing the sealed shutting of the peripheral chamber. The body of the device is provided at the distal end with more equidistant nerves for the guidance of the inner trocar. The inner diameter of the device body is of approximately 20 mm and the inner trocar of almost 12 mm. The aspiration at the level of the external chamber is made through a lateral coupling where a flexible tube can be attached.

The anchoring assembly is made up of four fixing rods inserted to the proximal end by a socket, while the distal end is provided with self-blocking hooks (fish hooks) that enter the cyst and complementarily fix the device at its surface. The inner diameter of the anchoring assembly must be chosen so as to guide the external cylindrical surface of the inner trocar with minimal clearance.


The inner trocar presents a thickness at the proximal end, provided with a sealing surface, of tronconic form, while in its inside, one could find a conic bore-hole in order to facilitate the guidance of the central tube and of other instruments; this bore-hole is limited by a cylindrical collar, necessary for the extraction of the inner trocar from inside the device body. The length of the trocar should be chosen in order that aspiration be accomplished and stabilize the two coaxial trocars, as well as the circumferential space between them.

Subsequently, an advance form of the device for the aspiration of the hepatic hydatid and ovarian cyst has been developed, in which the anchoring hooks are fixed in the lower end.

Another advanced variant of the device for the aspiration of the hepatic hydatid and ovarian cyst is made up of a transparent device for the secondary vacuum, that may close the

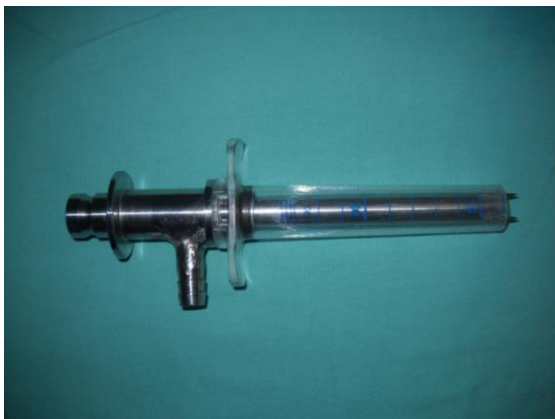aspiration by rotation, the advantage being the possibility of using it with one hand and at the same time, having the possibility of adjusting the aspiration debit and the vacuum applicability degree of the “coaxial trocar” assembly.

To the extent possible, all components of these devices were built with the possibility of detachment and separation, in order to receive optimal cleaning and sterilization.



Picture no. 30. The device for the aspiration of the hepatic hydatid cyst CHH

1 – Trocar of 20 mm 2- Mandren-trocar with thread 3 – Central trocar with anchoring assembly 4 – Body of the device for the aspiration of the hydatid cyst.



Devices for the aspiration of the hepatic hydatid cyst (CHH) - improved forms

## Laparoscopic hepatic hydatid cyst cure

The laparoscopic hepatic hydatid cyst cure represents a natural evolution of this condition surgery, especially following the technical progress and the progress made in celioscopic surgery. After multiple attempts of surgical surgery of this condition, it came to

the conclusion that laparoscopic surgery presents numerous advantages comparatively with the open surgery:

- excellent visibility;
- protection possibility with perifocal switches;
- possibility to work extraperitoneally, on working tunes of different calibre, imposed by the cyst;
- integral protection of the abdominal wall;
- very good endocystic visualisation;
- hemostasis and bilistasis with electrocautery, clip or suture;
- shorter length of hospitalization comparatively with open surgery

,but at the same time, it also presents certain disadvantages, which were put in shade by the first and improved surgeon's expertise:

- instrument palpation, which is proportional to the surgeon's training and experience / learning curve;
- capacity of liver suture;
- limitations on bilio-digestive anastomoses and the cysto-digestive ones.

Surgical laparoscopic surgery of the hepatic hydatid cyst, requires in addition to the standard instruments used in the upper abdominal laparoscopic approach, a series of specific instruments:

- device for the aspiration of the hepatic hydatid and ovarian cyst;
- 20 mm trocar for the installation of the protection switches;
- device for the fluidization of the hepatic hydatid cyst content;
- cold light source valve and interchangeable blades, to assist in addressing miniinvasive laparoscopic surgery, complementarily to the laparoscopic surgery;
- laparolift for the protection of accidental decompression in case of strong aspiration;
- two systems of simultaneous aspiration;
- optical telescope with working channel;
- rigid rod of 10 mm, round and useful to palpation;
- Liga-Sure™ forceps;
- electrocautery argon discharge.

Future needs for the improvement of the method and its completion will be linked to the new technological progress in medicine, in general and in laparoscopy in particular.

- high definition video camera and monitor;
- telescope with the possibility of changing the visibility angle;
- stapler for being used in laparoscopy;
- instruments with variable angles;
- echography with laparoscopic transducer for the deep intraparenchymatous cysts.

The anaesthesia necessary in the laparoscopic treatment of the hepatic hydatid cyst is the general anaesthesia with orthotracheal intubation, a necessity almost mandatory in laparoscopy and in upper abdominal surgery.

The patient's position on the operating table is in dorsal decubitus position with arms in abduction for infusions and tensiometer installation.

Surgeon surgical team consists of the surgeon, cameraman and two other assistants that will be located as follows:

- the surgeon will sit at the patient's left;
- the cameraman to the right of the patient;
- the first assistant will sit at the cameraman's left;
- the second assistant will be placed to the left of the surgeon.

In the first stage, laparoscopic approach is standardized, with the introduction of the trocars to view and approach the upper abdomen:

- supraumbilical optical trocar;
- a 5 mm trocar in the left upper quadrant;
- a 5-mm trocar in the right flank.

,the last trocars being placed according to the specific of the case, intrasurgically viewed topography of the cyst, the need for a perpendicular approach to the peri-cyst. A special placement, with specific technical details, if the cyst location is in the hepatic segment VII, is the transpleuro-diaphragmatic placement, preceded by sealing the intrapleural trajectory with the Reverdin needle or endo-close with the newer versions. The transpleuro-diaphragmatic placement will be detailed subsequently.

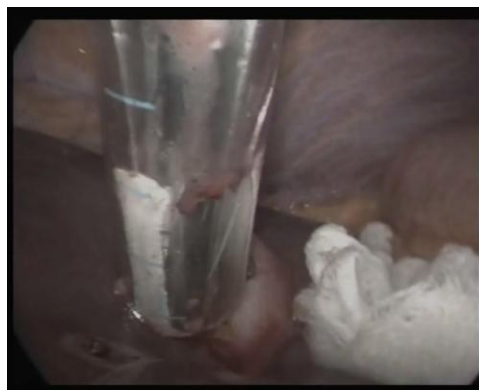After the insertion of trocars, the surgical field is protected by switches (switches placed in sealed cartridge with a 20-mm trocar), the orifice of the 20-mm trocar will be used

later for the introduction of the specific instruments. The 20-mm diameter trocar will be placed on the rigid rod and “screwed” in the hole with a “reamer:”

The device for the aspiration of the hepatic hydatid or ovarian cyst will be introduced through the hole of 20 mm with a guidance tool (rigid rod of 10 mm), this one being attached to the peri-cyst by sucking with the help of the secondary aspiration connected to the external trocar and by hooks anchoring. The treatment itself is performed by partial aspiration of the hydatid fluid and by scolicide fluid introduction (alcohol 90% or 20% saline) through the central axis of the suction device. 10 minutes later, one may extract the parasite. This can be done in three stages: initially, the inactivated hydatid fluid is extracted by aspiration, as well as the cyst content of sizes compatible with the central trocar diameter.

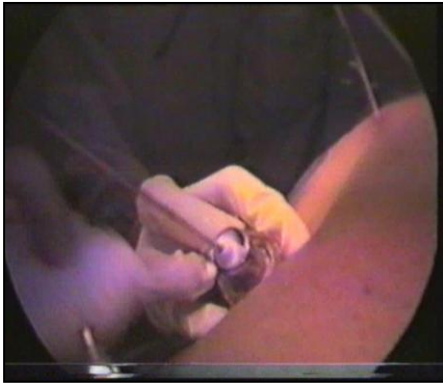The next steps consist of fragmentating the cyst content with the help of an electric mixer, then extracting the remaining liquid, of the the proliger membrane and of daughter vesicles by aspiration on the 12 mm central trocar simultaneously with the peripheral aspiration through the 20 mm trocar.

The device of for the aspiration of the hepatic hydatid cyst, of the false cyst of the pancreas and of the ovarian cyst, by the firm and sealed fixing (with the help of the hooks and of the second aspiration system) made at the peri-cyst level, plays an important part in preventing and contaminating the peritoneal cavity with hydatid liquid through the possible leaks.



In vivo aspiration at the level of the security trocar

The device for the fragmentation of the hydatid cyst accomplishes the morcellation of the parasitic content of large sizes (daughter vesicles, proliger membrane), at the same time melting down any viscous or corpuscular content, thus giving the possibility of extracting them through the 12 mm initial trocar or, if needed, through the peripheral trocar of 20 mm.



Fragmentation of the cystic content with the extraction of the brood membrane

The brood membrane may be frequently aspirated or, usually, in the event of impossibility of its aspiration, it can be extracted with forceps, in some cases on rod wrapping device for hepatic hydatid cyst content fragmentation.

The advantages of laparoscopic approach and the need for perpendicularly peri-cyst approach are demonstrated by the possibility or even the need to introduce the optical telescope with working channel through the endochystic trocar, checking the cystic cavity, extracting the remaining hydatid material, frequently closing any biliary communication or blood (rarely).

After having accomplished the previous operations, the remaining cavity lavage is practiced, as well as the disconnection of the aspiration system, the disconnection of the device from the surface and the assessment of the sizes of the subsequent peri-cystic resection or of the hepatic resection in healthy tissue, if the case may be.

Peri-cyst treatment is generally performed by maximum removal, for this purpose the scissors connected to electrocautery are used, as well as the bipolar electrocautery or with the help of the resection-sealing scissors (Liga-Sure™) by electrocoagulation, sometimes, by argon cauterization when extending the hepatic resection. In some cases, it was necessary to use hemostatic clips or stitches on the liver slice. Chysto-pericystectomy should be treated very carefully, due to the need of an optimal resection in order to avoid undersized resections, these ones predisposing to postsurgical retention complications and to a slow recovery, also being necessary to avoid over-sizing that can lead to unnecessary bleedings.

The treatment of the remaining cavity in different topographic variants has known two positions:

1. The renunciation of the spheroid plaque reduced by maximal extirpation (in topographic locations difficult to approach: segments VII-VIII or I, II, IV)
2. Peri-cystohepatoraphy relatively easy to segments III, IV, V, VI, but dependent to the relationship with the hepatic channels, especially for segments IV-V, miniinvasively and laparoscopically achievable through the 2-4 cm wound, using the narrow valve with optical fibre and the Reverdin needle or the aponeurotic suture needles used in laparoscopic surgery.

Remaining cavity drainage is mandatory in case of their unsutured abandon, sometimes using the intracavitary drainage after suture as well, the exteriorization of the drainage tubes being performed on straight tracks as short as possible, I also used the transpleurodiaphragmatic drainage with preliminary transparietal pleural sealing with Reverdin needle.

Sometimes, I also used the additional drainage of the abdominal cavity near the remaining cavity, in the aspiration spaces or in Douglas bag bottom, as a further safeguard.

A particular situation is represented by the hepatic hydatid cysts located at the level of segment VII, especially those that are expressed in the bare area of the liver. Abdominal approach is the standard one, with the introduction of optical trocar over the belly button after accomplishing the working chamber by the introducing of the carbon dioxide with the help of the Veress needle.

Abdominal cavity is then inspected to confirm the diagnosis and the localization of hydatid cyst, two working trocars will be inserted in the epigastrium and right flank, as required. Pericystodiaphragmatic adhesions signal us the existence of the cyst at the level of the posterior hepatic dome a location which previously was unapproachable, which also presents a high risk due to the proximity of vena cava and of the right suprahepatic vein. Dissection of the peri-cystodiaphragmatic adhesions is practiced, the approach being close to the cystic wall, both to the instrument and to the optic telescope, which makes it difficult to accomplish a secure approach, without leakage of cystic content at the level of the peritoneal cavity, as well as difficulties in visualizing the cystic cavity, subsequently.

The introduction of an additional working trocar of 20 mm the level of the VII-VIII right intercostal space on the average anterior or posterior axillary line, its position being established by the topography of the cyst sizes requires a central and a perpendicular approach on the surface of the cyst. The trocar helps in the initial switching with alcohol, afterwards playing the part of the main working trocar. The trocar is inserted after the partial dust of the lung through transparietal or transdiaphragmatic puncture and the after the accomplishment of a limited parieto-diaphragmatic pleurodesis of the pleural right lateral bag bottom with the help of aponeurotic suture needles from the laparoscopic surgery (Endoclose, Aesculap, Wolf) or of the Reverdin needles.

Lung re-expansion will also be performed by puncture, but this time by aspirative puncture, while the post-surgical pleural drainage not being often necessary. The drainage of the cyst cavity has been made by the externalization of the tubes through the transpleurodiaphragmatic plague.



The evolution of the cases which have been treated laparoscopically may be astonishingly rapid (3-7 days of hospitalization) and highlighted a number of reduced complications, in terms of gravity, comparatively with the open surgery.

The restrictions of the laparoscopic treatment of the hydatid cyst are the general restrictions of laparoscopy, which are permanently under improvement, as well as those related to the central location of the cyst, the approach possibility being linked to the access to the intrasurgical echography with laparoscopic transducer, locations that are quite difficult in the open surgery.

In certain situations, cyst topography required colecystectomy in block with maximal peri-cystectomy.

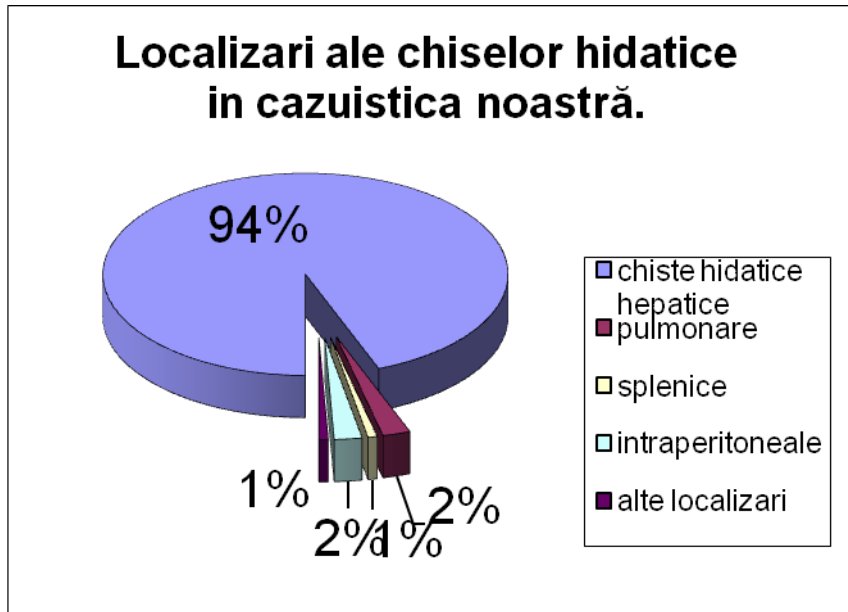
Hepatic suture considerably shortens the evolution (3-5 days) (in the conditions of a previous experience in the open surgery), also having the obvious cosmetic benefice of the miniinvasive approach.

Switching isolation, taken from the open surgery, confers a plus of certainty to laparoscopic surgery against contamination.

Sometimes, general or contact oddien spasmolytics can be used in post-surgical general bleeding.

Pericystophrenic take off may bring about the diaphragmatic perforation, which can be solved by laparoscopic suture, rather without abdominal drainage, but with the pre-surgical aspiration of the pneumothorax. Switches represent an additional phrenic protection factor.

## RESULTS AND DISCUSSIONS



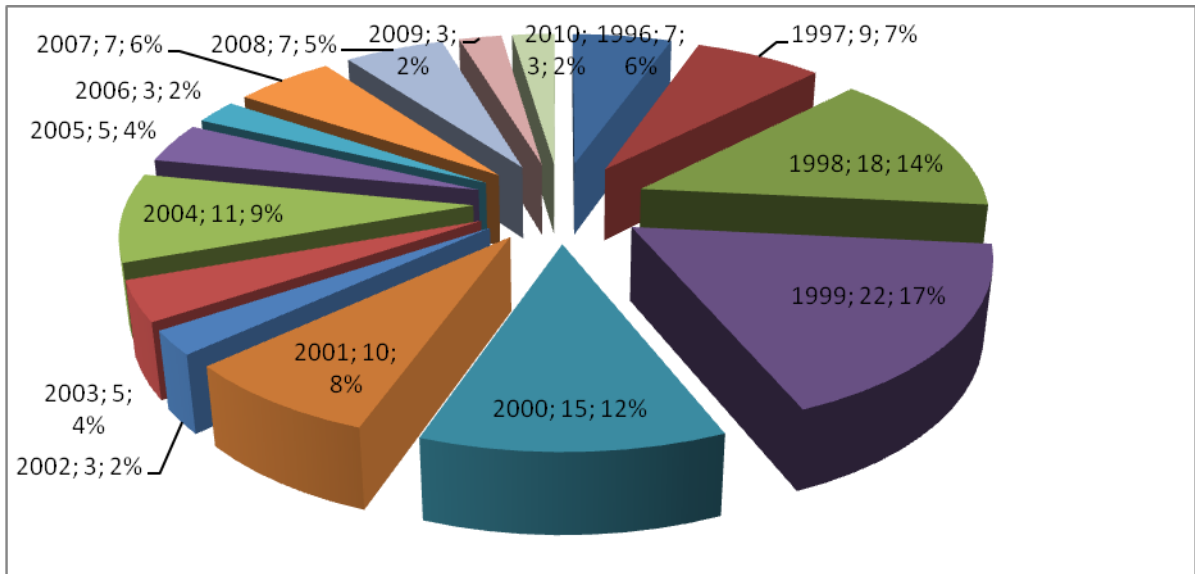
Localisation of hydatid cysts

Localisation of hydatid cysts at the level of the Surgery Clinic II within the Emergency County Hospital of Sibiu was illustrated in percentage, that shown in the chart above, emphasizing an evident predominance of hepatic hydatid cysts (94%), followed by lung hydatid cysts, those at the level of the peritoneum, spleen and other locations. These localisation options are also dependent to the hydatid cyst topography, mainly hepatic, but also to the specific of the clinic the study took place in.

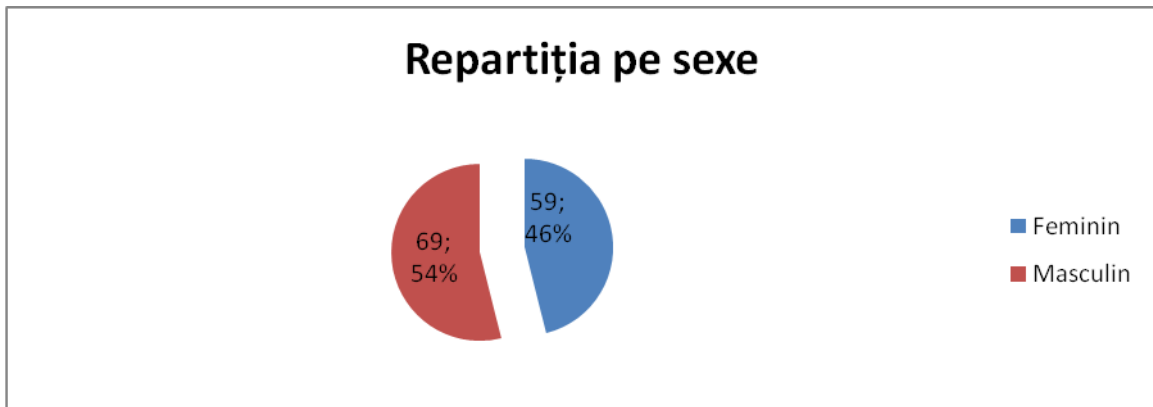
The annual repartition of cases of hydatid cysts, operated at the level of the three analysed settings, shows a tendency for the decrease of the number of patients with this pathology, with a top point registered in the 1999, with 19 operated cases, representing 17 % of the operated cases, all along those 15 years.

| Annual average of cases | Standard deviation | Number of years |
|-------------------------|--------------------|-----------------|
| 8,53                    | 5,13               | 15              |

Table no. 2 Annual average of hepatic hydatid cysts cases



Annual repartition



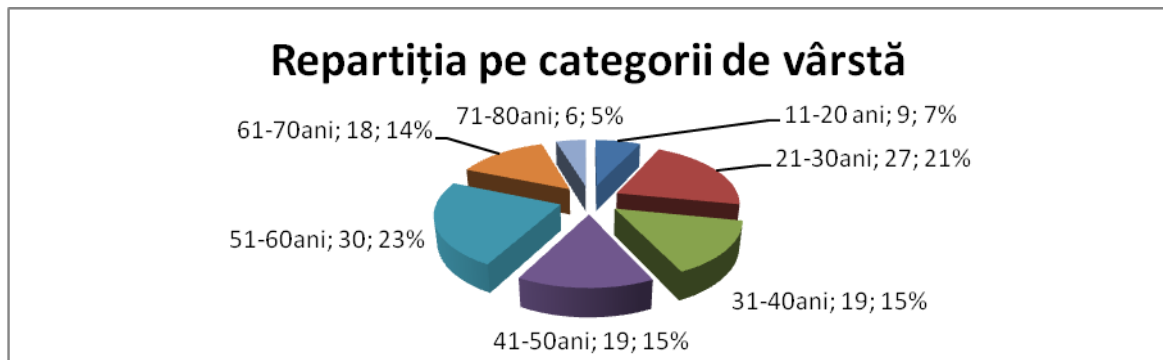
Gender distribution

Dispersion on gender groups shows a slightly higher proportion for males, different data from those in the international literature where the proportions are reversed or equal. This difference may occur due to the involvement of the male gender in activities of animal breeding and care in our country.

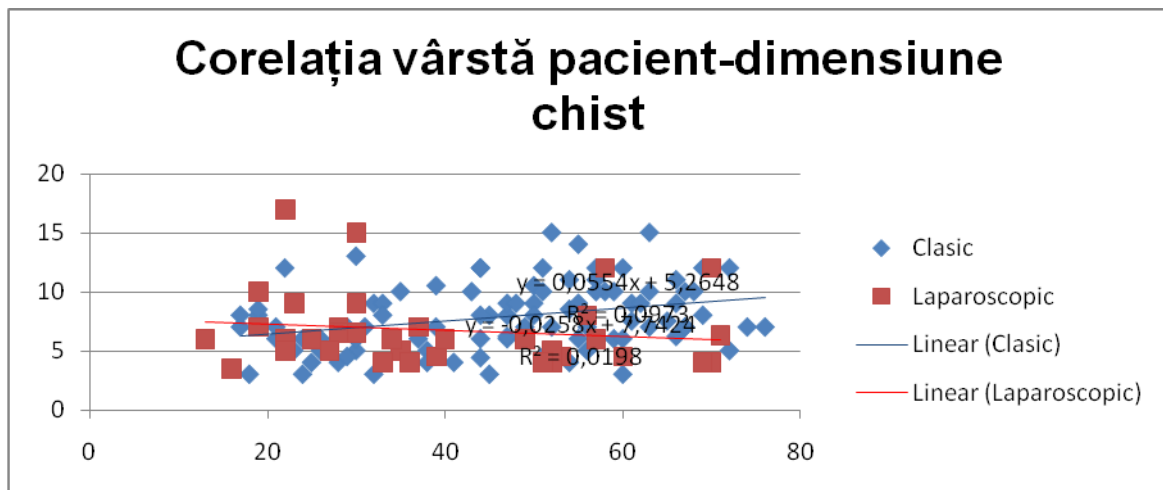
The best age groups represented in our statistics are those between 51 and 60 years old and between 21 and 30 years, explained by the fact that patients between 21 and 30 years receive better medical services, especially ambulatory investigation services, subsequently benefiting from surgical interventions.

Between 51 and 60 years old, addressability is higher due to the length in time of the cysts, these patients being cyst-carriers for years, thus offering more expressed symptoms, reason for which such patients require further investigation and treatment.

Extreme ages, under 18, are most commonly treated in Paediatric Surgery services, while the patients over 70 years do not generally present the disease, this one being previously treated or the contact with the source is no longer so frequently.



Age distribution



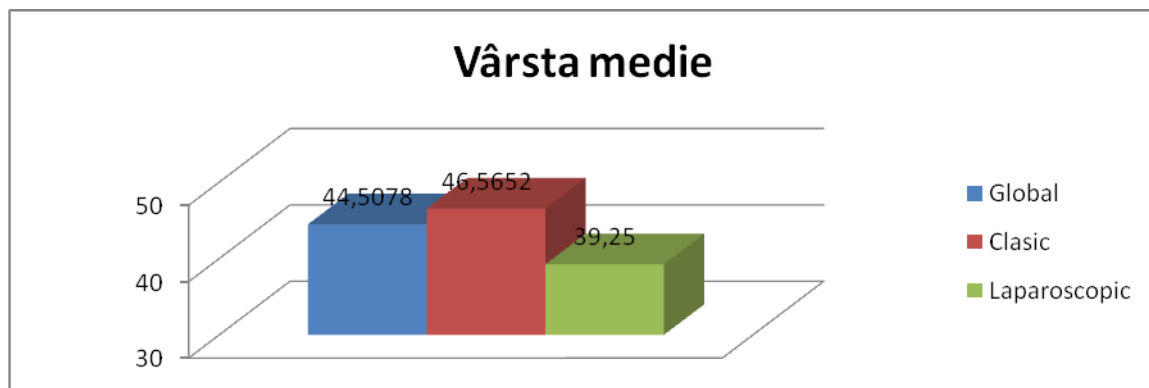
Correlation between age and size of the cyst

From the chart presenting the correlation between the patient's age and cyst size, it result the possible length of cysts, which for hepatic location, have a decreasing rate between 1 and 5 cm per year, closer to the minimum value. The correlation indices are  $R = 0.3119$  for the cases that occurred in open surgery and  $R = -0.1407$  for cases in which laparoscopic surgery intervened.

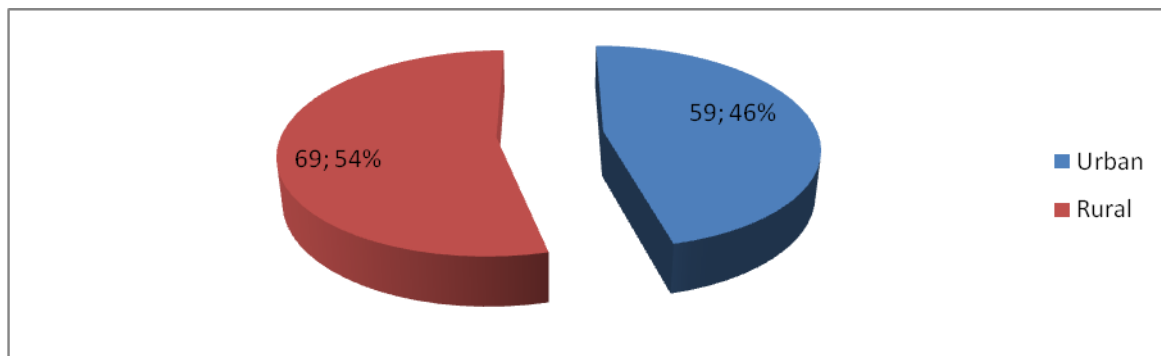
|                      | Average age | Standard deviation | n  | p      |
|----------------------|-------------|--------------------|----|--------|
| Classic surgery      | 46.57       | 15,95              | 92 | 0,0236 |
| Laparoscopic surgery | 39.25       | 16,97              | 36 |        |

Average age of the patients (cases treated classically and laparoscopically)

The average age of patients presenting this condition, operated and included in our statistics, was of 46.57 years old for cases where the intervention was classic and of 9.25 years old laparoscopically operated, the difference being statistically significant with  $p < 0,05$ . The younger age of the patients who were operated laparoscopically can be explained by a better addressability of the young people for laparoscopy, especially in early stages of this method of treatment in the case of this pathology (1996-2000).

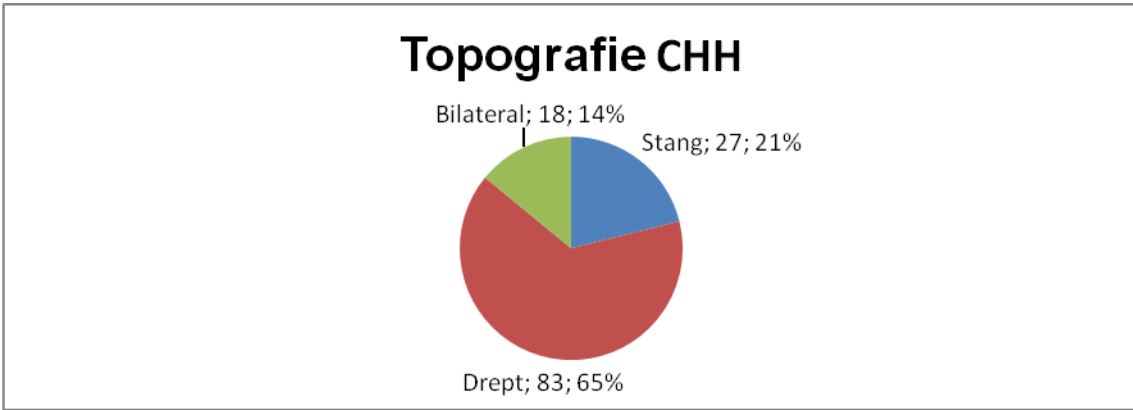


Average age of the patients



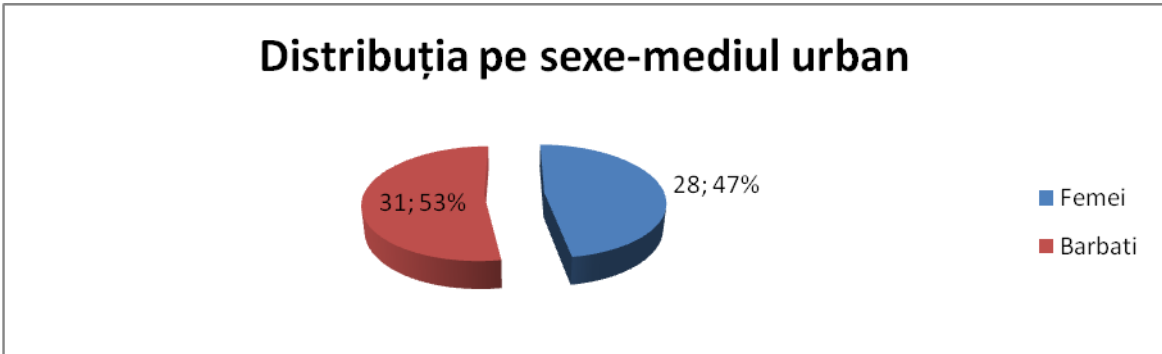
Patients' origin environment

Data on the backgrounds of patients are consistent with the international literature, the frequency of rural patients suffering from zoonoses being in general higher than those in urban areas, mainly due to more frequent and longer contact with the affected animals, but also due to the lack of treatment for these animals. However, the tendency is to balance the number of patients from the two areas (urban and rural), probably due to decreased number of livestock farmers in the rural areas, of the increasing number of dogs in the urban areas and due to the increase percentage of urban population, what globalization and urbanization actually means.

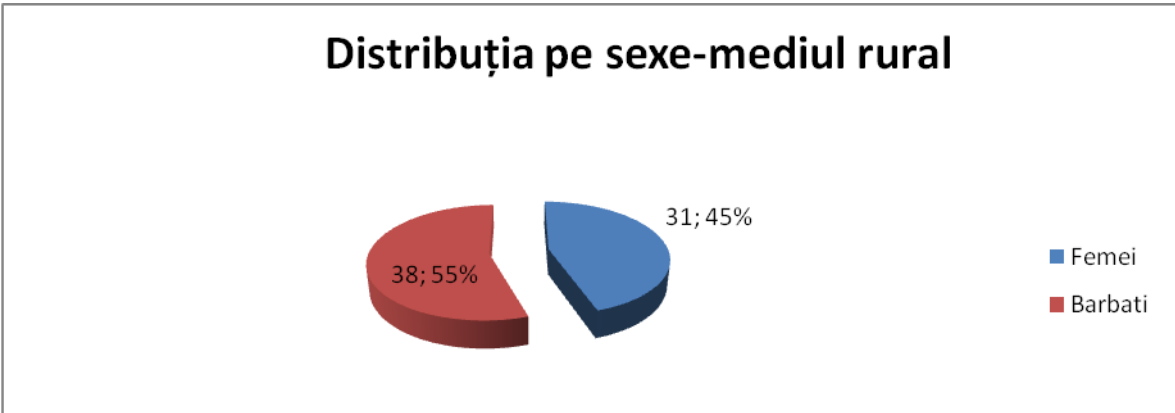


Topography of the hepatic hydatid cyst

Cysts topography obeys by the liver volume and its portal vascularization, the cysts location being dependent to the blood quantity that reaches the level of each lobe through the portal vein, blood that transports the hexacant embryos, those who are transformed in metacestodes at the level of the liver, in the context of absorption at thick intestine level and at the level of the left half of the colon (upper mesenteric territory) and of the portal laminar flow.



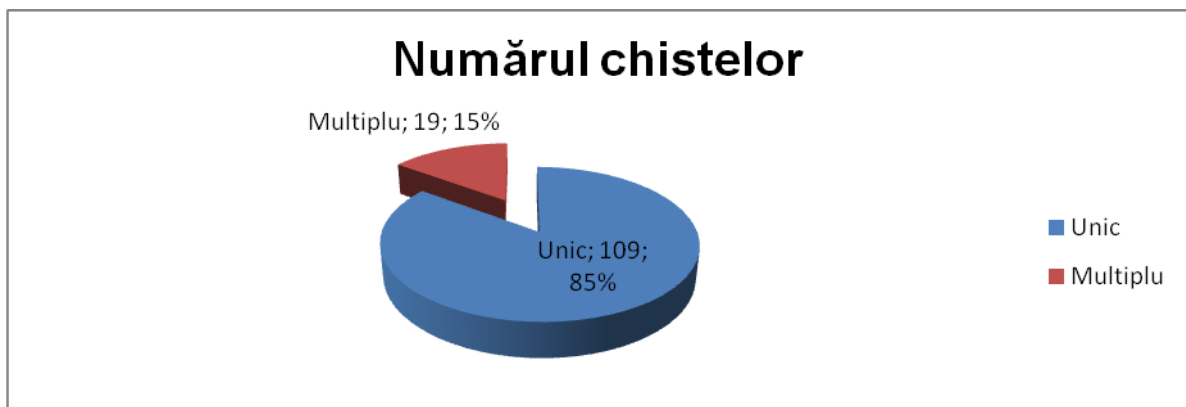
Patients' distribution per gender in the urban environment



Patients' distribution per gender in the rural environment

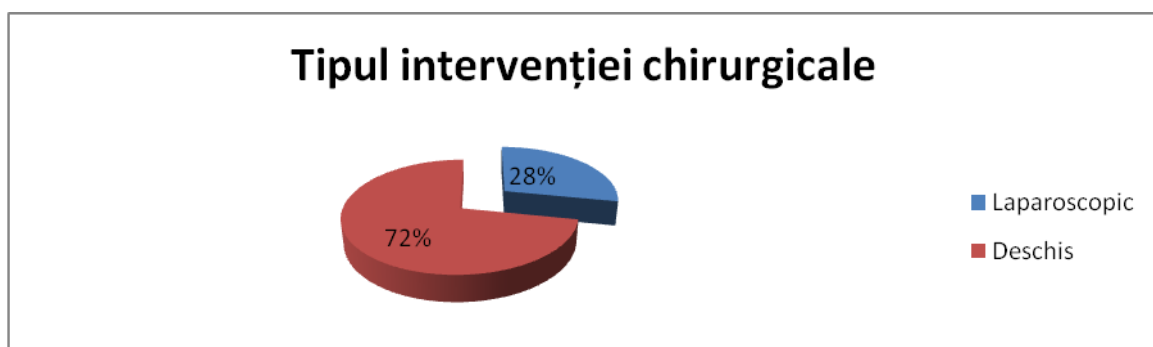
The previous charts show the compliance of proportions per gender and origin environment groups in relation to the overall distribution by gender, with no statistically significant differences between urban and rural ( $p = 0.8593$  determined by the Fischer test).

The proportion of the unique and multiple hydatid cysts in the studied batched have been taken into consideration, this one being net favourable to the unique cysts, with 109 cases (85%), a normal proportion given the existence of *Echinococcus granulosus* species in our country, that are rarely presented under the form of multiple cysts, especially in adults. The following charts illustrate this proportion in terms of number and percentage.



#### The number of cysts

Other studied parameters are those related to the classic operations, laparoscopic respectively. The patients included in the study group have fully benefited from surgical interventions, 92 of them benefiting from traditional surgery and 36 patients of laparoscopic interventions. Of the 92 traditional interventions, 3 are conversions after the laparoscopic approach, one of which being a conversion to miniinvasive surgery, being detailed in a previous chapter, in this case a perichisto-duodeno anastomosis being practiced. Largot operculectomy, and if the cysts were located in segments 2-3, atypical hepatic bisegmentectomy have been performed.

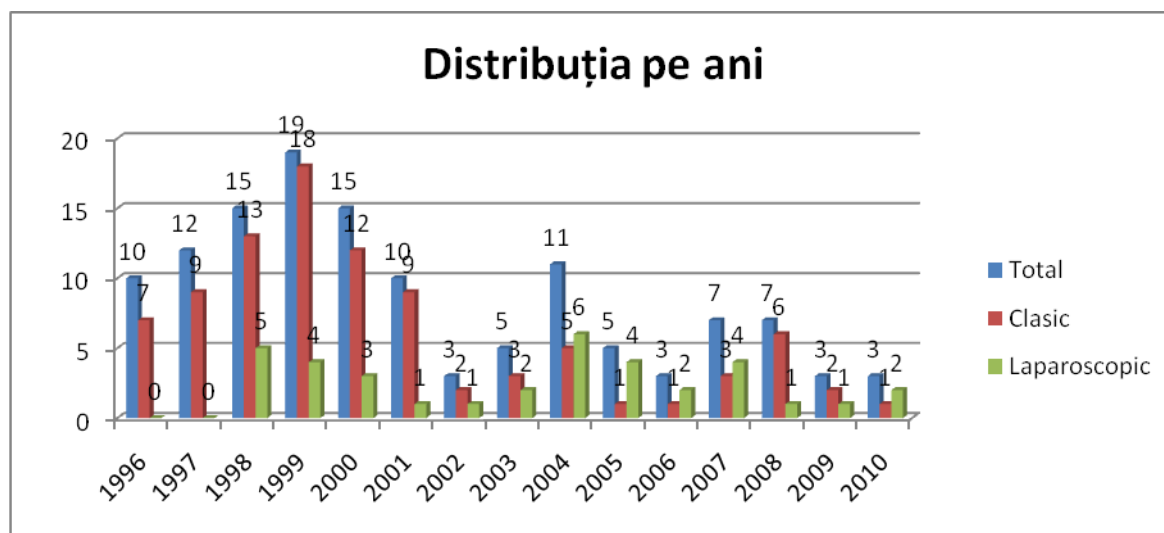


Type of the surgical intervention (open/laparoscopically)

In percentages, 72% of the patients have been openly treated and 28% laparoscopically. The age distribution of the laparoscopically treated patients, show us a progressively increasing distribution in terms of percentage, with a maximum of six cases in the year 2004. It can also be observed that between 2004-2007 and in the year 2010, the number of cases treated laparoscopically exceeded the number of cases classically treated. During those fifteen years taken into the study, the first two years are the years when no laparoscopic interventions have been made, but only open interventions. The annual average of the laparoscopically treated cases, starting with the year 1998, year which marked the beginning of laparoscopy in the treatment of the hepatic hydatid cyst at the level of the Surgery Clinic II of the Emergency Clinical County Hospital of Sibiu, was of 2,769, in percentages, the cases treated laparoscopically represent 32,14%.

|                      | Annual average | Standard deviation | n  | p      |
|----------------------|----------------|--------------------|----|--------|
| Classic surgery      | 6.13           | 5.17               | 15 | 0.0135 |
| Laparoscopic surgery | 2.40           | 1.84               | 15 |        |

Table no.4. Annual average within the studied period of time (15 years)

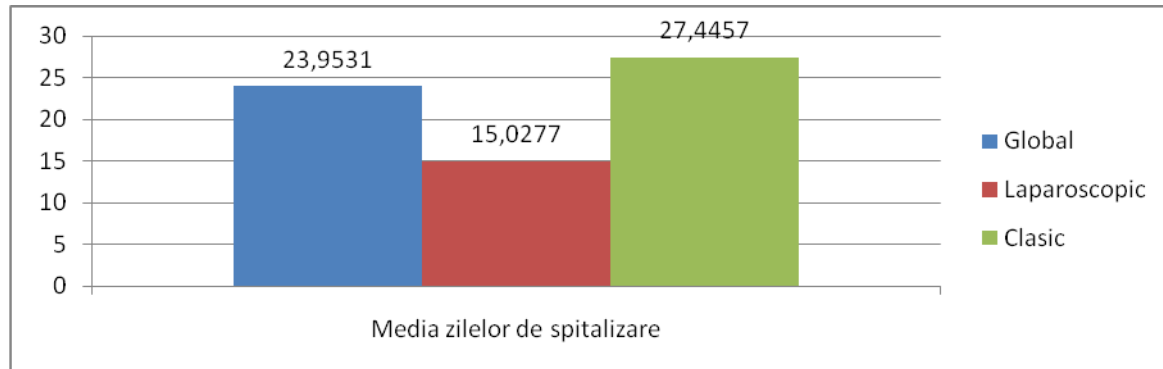


Annual distribution

One of the most representative criteria for the efficiency, usefulness and benefices brought by a type of treatment introduced in the current practice is that of the average number of hospitalization days, this parameter being significant because all patients have been discharged surgically cured.



The global average of hospitalization is of 23,95 days, and results from the average of the hospitalization days of those 92 cases, openly treated (27,44 days), the cure being more rapid in laparoscopic intervention due to the minimal aggression of the abdominal wall. The statistic computation for the two batches show a  $p < 0,05$ , with a result of 0,0001 what is considered highly significant from the statistics point of view.

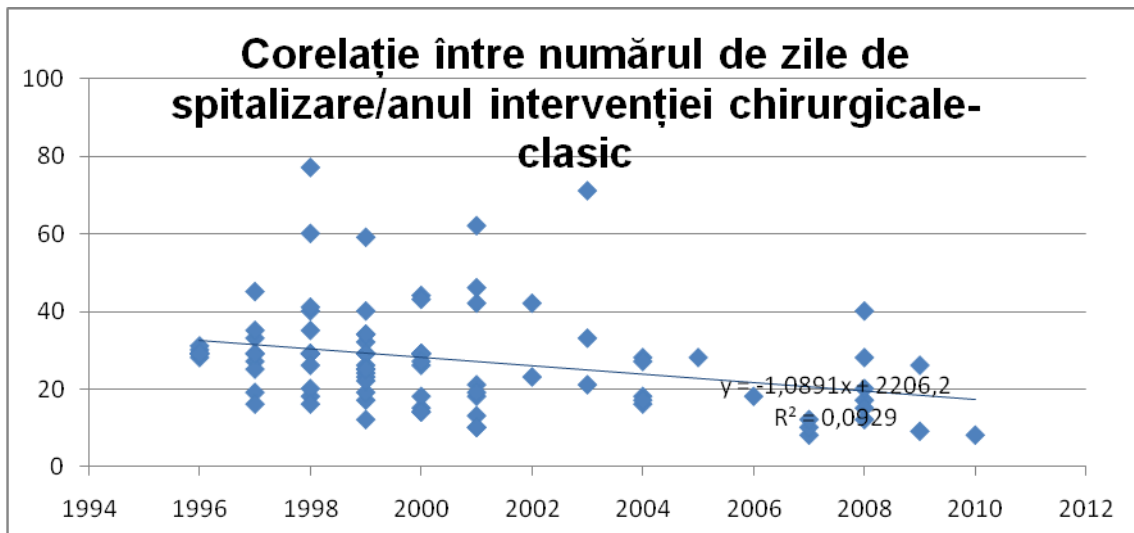


Average length of hospitalization

Also, patients obviously feel less pain in laparoscopic interventions, evisceration is non-existent, laparoscopic surgical wound bleedings are very rare, as well as postoperative wound infection. In the case of the studied batch, I did not register any immediate postoperative complications of the abdominal wall.

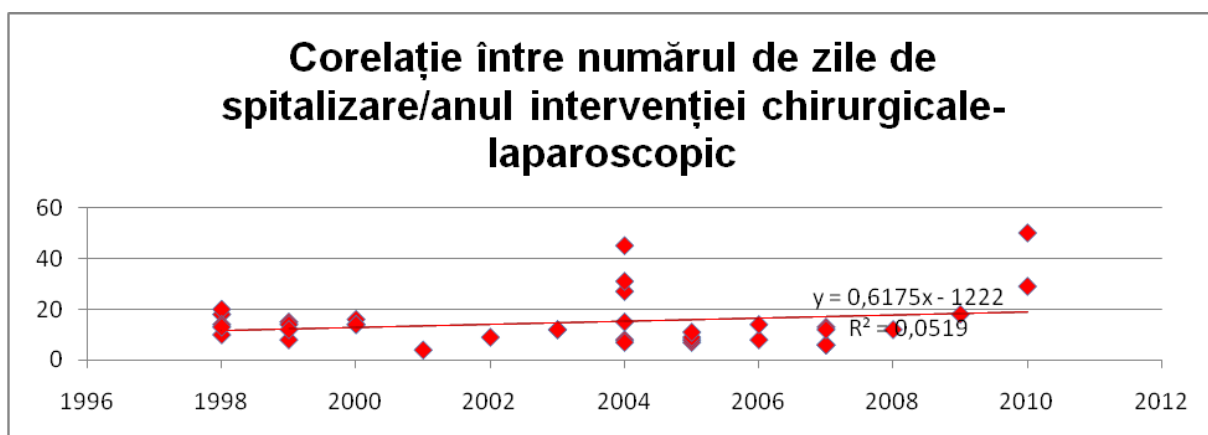
|                    | Classic surgery | Laparoscopic surgery |
|--------------------|-----------------|----------------------|
| Average            | 27,45           | 15,03                |
| Standard deviation | 13,04           | 10,06                |
| p                  | 0,0001          |                      |
| n                  | 92              | 36                   |

Average length of hospitalization



Correlation between the year of the surgical intervention and the number of hospitalization days (cases operated by the classic methods)

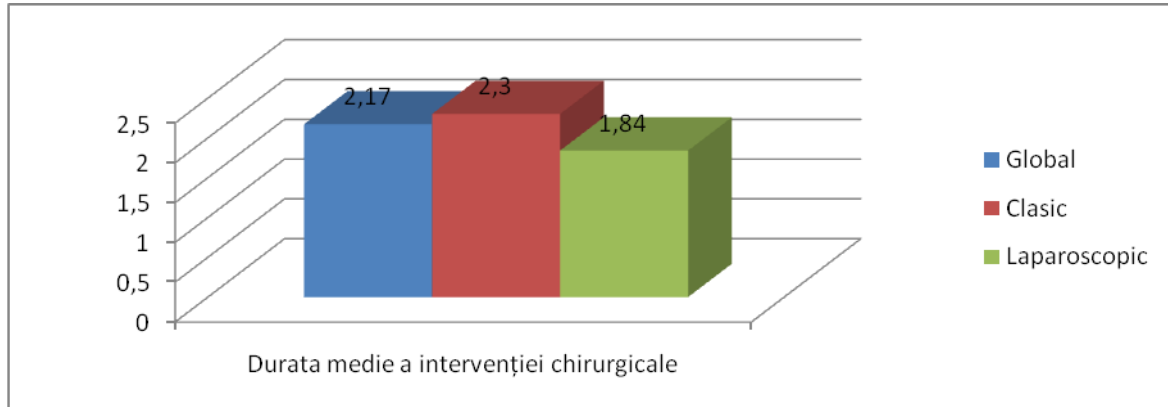
The charts of correlation between the year of surgery and the number of hospitalization days do not considerably differ, being almost constant in case of laparoscopic and classic interventions, the results not being influenced by the learning curve. The correlation coefficients are: in the case of classically treated cases, of -0.30478, and in the case of laparoscopically treated cases, of 0.22781. The slight increase in the length of stay towards the end of the analysed period is more correlated with the increase of complicated cases laparoscopically approached.



Correlation between the year of the surgical intervention and the number of hospitalization days (cases operated by laparoscopic procedure)

The average duration of surgery is another factor taken into account in the statistics presented, which is an average of 1.84 hours for the cases treated laparoscopically and 2.3 hours for cases treated by open surgery, with a  $p = 0.0031$ , statistically significant. This difference may have two explanations: the cases that occurred in open surgery were operated

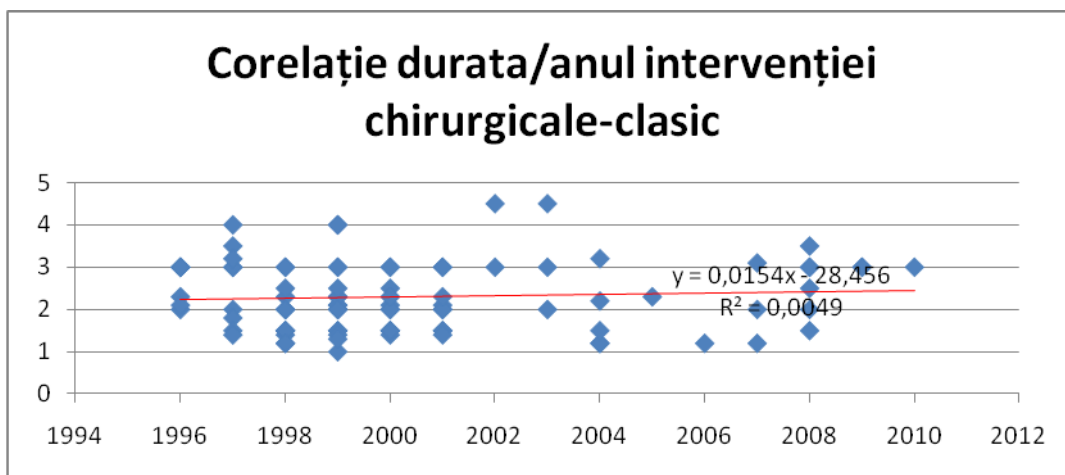
by several surgical teams, not necessarily trained together, the laparoscopic batch being approached and operated by a single, very consolidated team and with expertise in laparoscopic surgery, whose members have been changed, but the main operator remaining the same. In one single team approach, the learning curve made a difference.



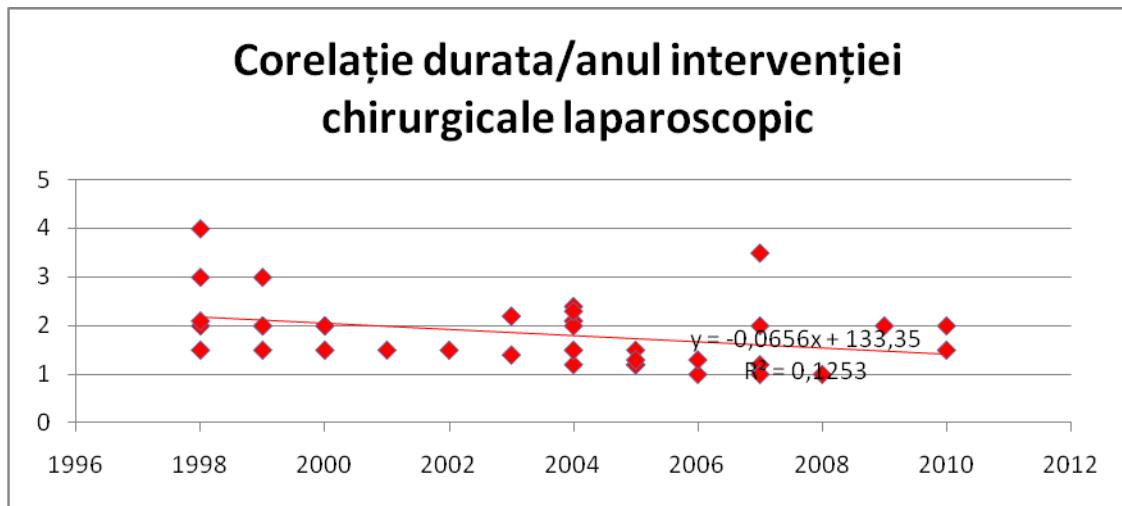
Average length of the surgical intervention (hours)

|                           | Average length | Standard deviation | n  | p      |
|---------------------------|----------------|--------------------|----|--------|
| Classic intervention      | 2,3            | 0,799              | 92 | 0,0031 |
| Laparoscopic intervention | 1,84           | 0,688              | 36 |        |

Average length of the surgical intervention (hours)

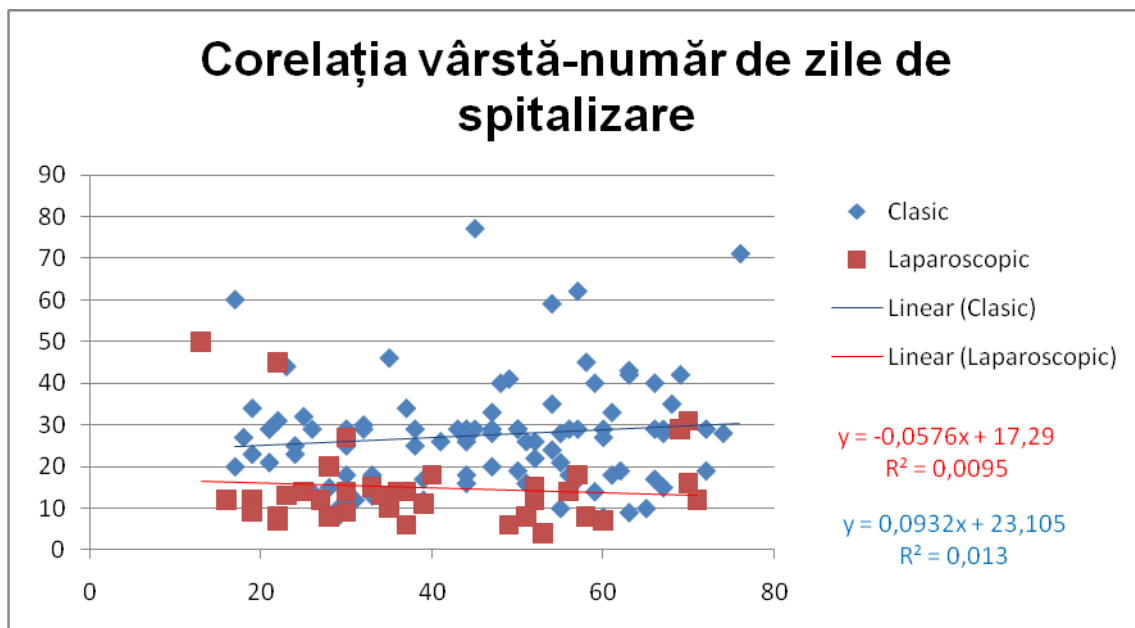


Correlation between the year of surgery and the average length of the surgical intervention (cases operated by classic methods)



Correlation between the year of surgery and the average length of the surgical intervention (cases operated by laparoscopy)

As shown in the chart above, the length of the intervention had a minimal increase in the case of the batch where the open surgery was performed, over the 15 studied years, with a correlation coefficient  $R = 0.070257874$  and a decrease in the case of the batch where laparoscopic intervention was performed, with a correlation coefficient,  $R = -0.353930$ , which shows a significant correlation of the length decrease with the surgery year, although the seriousness of cases approached laparoscopically has increased significantly.



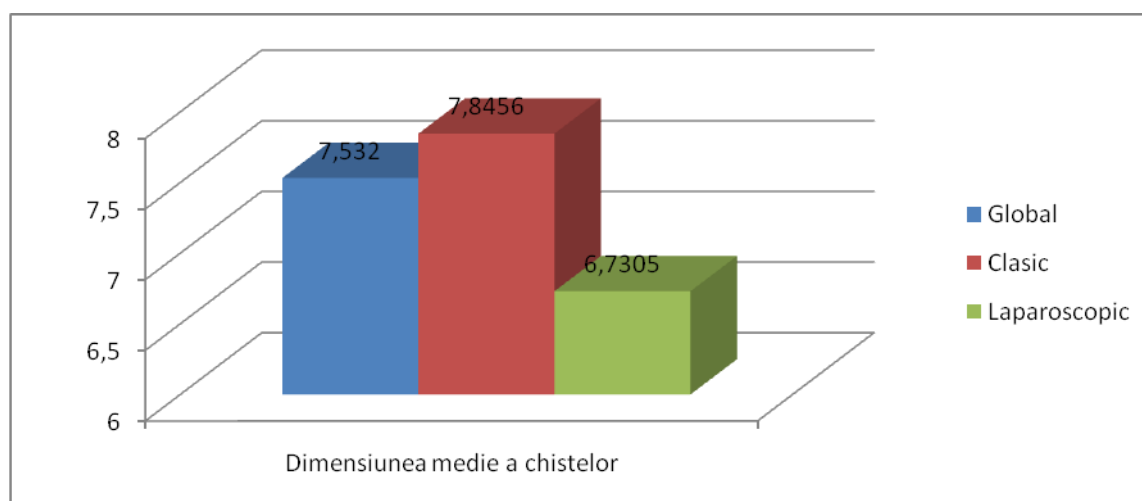
Correlation between the patient's age and the days of hospitalization

Another chart is that of the correlation between age and the number of days of hospitalization, data which were positively correlated in the case of the open surgery (age

increase brought about the increase of the hospitalization length) with a positive correlation coefficient,  $R = 0.113945$ , but they were negatively correlated for laparoscopic interventions (age increase brought about the decrease of the number of hospitalization days) with a negative but weakly associated correlation coefficient,  $R = -0.09724$ .

|                      | Average size of the cysts | Standard deviation | p      | n  |
|----------------------|---------------------------|--------------------|--------|----|
| Classic surgery      | 7,846                     | 2,833              | 0,0537 | 92 |
| Laparoscopic surgery | 6,731                     | 3,109              |        | 36 |

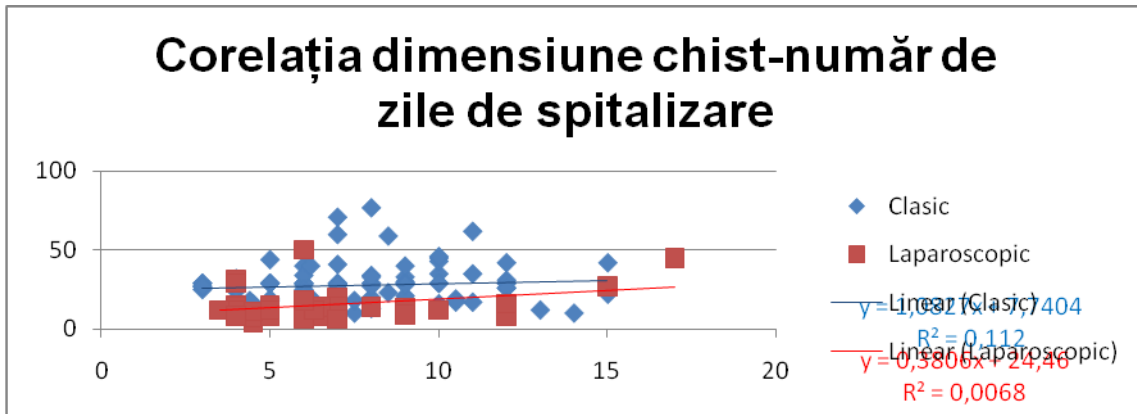
Average size of the cysts



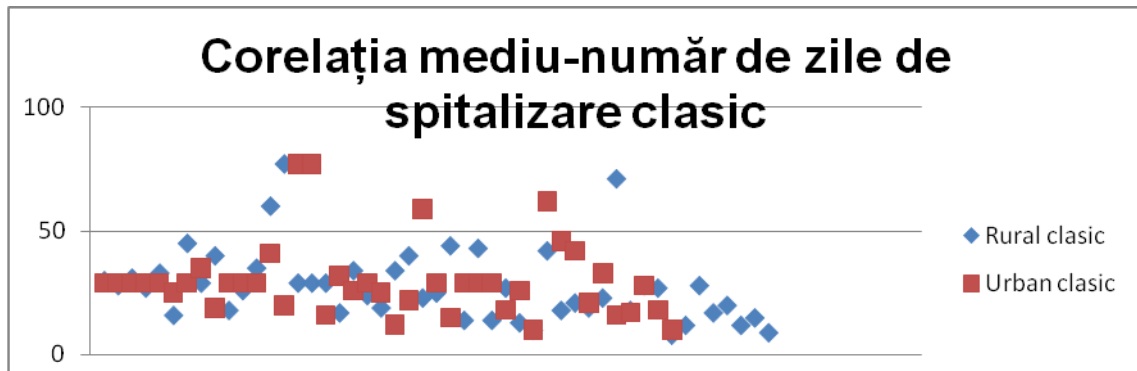
Average size of the cysts

The size of the cysts is another extremely important factor in the case of the studied batches, this one being on average of 7,532 cm, with 7,8456 cm for the cases operated classically and with 6,731 cm for the cases operated laparoscopically, with a  $p=0,0537$ , conventionally outside the statistical significance limit.

Another studied correlation chart is one that emphasize the influence of the cyst sizes on the hospitalization length, the correlation coefficient being in the classic batch,  $R=0,082651$ , the influence of the cyst size being poorly correlated with the number of hospitalization days, and in case of the laparoscopic batch,  $R=0,334607$ , being more significant.



Correlation between the cysts size and the number of hospitalization days



Correlation between the patients' origin environment and the number of hospitalization days (cases operated by classic methods)

| Classic method | Average | Standard deviation | n  | P     |
|----------------|---------|--------------------|----|-------|
| Rural          | 27,57   | 14,51              | 49 | 0,922 |
| Urban          | 27,30   | 11,31              | 43 |       |

Correlation between the patient's origin environment and the number of hospitalization days (cases operated by classic methods)

The correlation between the patient's origin environment and the number of hospitalization days show, for the cases, treated classically, a minimal difference between the rural patients and the urban ones, with a plus for those coming from the rural environment,  $p=0,922$ , the statistical significant being reduced.

| Laparoscopic surgery | Average | Standard deviation | n  | P      |
|----------------------|---------|--------------------|----|--------|
| Rural                | 16,10   | 10,19              | 20 | 0,4827 |
| Urban                | 13,69   | 10,06              | 16 |        |

Correlation between the patients' origin environment and the number of hospitalization days (cases operated laparoscopically)



5. Using our proposed process for laparoscopic treatment of hepatic hydatid cyst bring many real benefits.
6. The use of the procedure we proposed for the laparoscopic treatment of the hepatic hydatid cyst brings some real benefits
7. Hepatic hydatid cyst laparoscopy observes all standards imposed by the classic surgery.
8. Laparoscopic surgery of hepatic hydatid cyst is superior to open surgery due to the fact that it preserves the integrity of the abdominal wall, with less postoperative pain.
9. Visibility at the level of the cystic, abdominal cavity is superior in the laparoscopic procedures due to the telescope magnification (4-6x).
10. The use of new technical equipment (cameras and high-definition monitors, telescope with adjustable viewing angles, intrasurgical ultrasound with laparoscopic transducer) is considered advantages of the laparoscopic interventions.
11. Laparoscopy may bring the possibility to visually inspecting the cyst cavity.
12. The device for the aspiration of the hydatid and ovarian cyst (OSIM 120809/30.04.2008 Patent - Univ. Dr. Dan Sabau) is a device designed for the laparoscopic treatment of the intra-abdominal cystic formations (hydatid cyst, ovarian cyst, pancreatic pseudocyst etc.)
13. The device for the aspiration of the hydatid and ovarian cyst (OSIM 120809/30.04.2008 Patent - Univ. Dr. Dan Sabau) provides an efficient protection of the abdominal cavity, preventing the secondary insemination and the hepatic fluid leakage by creating an extraperitoneal working tunnel.
14. Compared with other devices of laparoscopic treatment of the hydatid cyst, the device for the aspiration of the hydatid or ovarian cyst offers the advantage of a firm fixing at the level of the peri-cyst through the vacuum created by the secondary aspiration system and by the self-fixing hooks.
15. The device for the fluidization of the hepatic hydatid cyst (OSIM Patent no. 120810/30.04.2008 - Univ. Dr. Dan Sabau) offers a real solution for the laparoscopic treatment of cysts with dense content that can not be aspirated.
16. The hepatic hydatid cyst is a condition that stimulated surgeons' creativity by its complexity and requirements imposed by such a treatment.
17. The learning curve is essential in laparoscopic surgery in general and in the laparoscopic surgery of the hydatid cyst, especially.
18. The cases treated laparoscopically did not register any recurrence of the disease.



19. The length of hospitalization is an extremely important factor in establishing the healing speed of the patient, which is considerably reduced in the case of the above-described laparoscopic technique.
20. The patients operated by laparoscopic techniques did not register any immediate or tardy parietal complications, frequent complications in the case of large-sized incisions in the surgical cure of the hepatic hydatid cyst treated openly.
21. Laparoscopic surgical treatment of the hepatic hydatid cyst should be associated to the antiparasitary medication treatment.
22. The preferred solution in this case is prophylaxis.

## Bibliography

1. [Abu-Eshy SA](#). Clinical characteristics, diagnosis and surgical management of hydatid cysts. *West Afr J Med*. 2006 Apr-Jun;25(2):144-52. Review.
2. Acarli Koray- Controversies in the laparoscopic treatment of hepatic hydatid disease. *HPB (Oxford)*. 2004; 6(4): 213–221
3. Acunas B, Rozanes I, Celik L, et al. Purely cystic hydatid disease of the liver: treatment with percutaneous aspiration and injection of hypertonic saline. *Radiology*. 1992;182(2):541-543.
4. [Adamek B, Wilczek K, Wiczowski A](#). Echinococcus granulosus--diagnostics and therapy problems--case report *Pol Merkur Lekarski*. 2006 May;20(119):560-2. Polish.
5. Akhan O, Baykan Z, Oguzkurt L, Sayek I, Ozmen MN. Percutaneous treatment of a congenital splenic cyst with alcohol, *European Radiology*, 1997, vol. 7, no. 7, pag. 1067
6. Altamar A, Mircioiu C, Pop CE. Tratatul chirurgical al chistului hidatic hepatic, *Sibiul Medical*, 1998, anul IX, nr. 4, pag. 343
7. Amitai Bickel, MD; Norman Loberant, MD; Jonathan Singer-Jordan, MD; Moshe Goldfeld, MD; George Daud, MD; Arie Eitan, MD - The Laparoscopic Approach to Abdominal Hydatid Cysts.A Prospective Nonselective Study Using the Isolated Hypobaric Technique. *Arch Surg*. 2001;136:789-795
8. Angelescu N. Tratat de patologie chirurgicală, vol.II, Ed. Medicală, București, 2001, pag. 1840-1848.
9. [Arjansiri K, Charoenrat P, Kitsukijit W](#). Anatomic variations of the hepatic arteries in 200 patients done by angiography. *J Med Assoc Thai*. 2006 Sep; 89 Suppl3:161-8.
10. Așchie Ion-, Tratatul chirurgical al bolii hidatice hepatice, Editura Medicală, București, 2000
11. Bardac OD - Clasic si modern in chistul hidatic hepatic, Ed. "Mira Design", Sibiu, 2002
12. Beuran M. – Manual de chirurgie, Ed. Universitară "Carol Davila", București, 2005
13. Bismuth H. - L'anatomie du foie et les techniques des hepatectomies. *Ann. Chir*. 1998; 52: 61-63
14. Bismuth H., Houssin D.,Castaing D.,Major and Minor Segmentomies "Reglees" in Liver Surgery, *World J. Surg.*, 1982,6:10
15. Bismuth H., Sherlock D.J.-Revolution in Liver Surgery, *J.Gastroenterology and Hepatol.*,1990,Suppl 1:95
16. Bortoletti G, Gabriele F, Seu V, Palmas C-.,Epidemiology of hydatid disease in Sardinia: a study of fertility of cysts in sheep, *J.Helminthol*, 1990 Sep, 64(3),212-6
17. [Botea F, Sarbu V, Dima S, Iusuf T, Unc O, Toldisan D, Pasare R](#). The role of intraoperative ultrasound in the diagnosis and treatment of hydatid liver disease *Chirurgia (Bucur)*. 2006 Nov-Dec;101(6):593-8. Romanian.
18. Boțianu A.M: Chistul hidatic toracic, *Tipografia UMF Cluj-Napoca*, 1995, 9-11
19. Boumati LM, Cassiles LMC, Crisonto L, Rouchere O, Torrico C. Differentiation of healthy from cirrhotic livers: evaluation of parametric images after contrast administration in magnetic resonance imaging, *Investigative Radiology*, 1996, vol. 31, no. 12, pag. 768.
20. Bouree P, Hydatidosis: Dynamics of Transmission, *World J. Surg*, 2001, 25, 1:4.
21. Bratu D., A.D.Sabău, D.Sabău- Tratatul laparoscopic al chistului hidatic hepatic- prezentare de caz-.,*Acta Medica Transilvanica*”, Anul X-2005 Nr. 2-pag 57.
22. Bratu D., A.Sabău, D.Sabău, A.Dumitra, A.Coman, C.Lupuțiu-.,Limitele laparoscopiei în tratamentul chistului hidatic hepatic”-Prezentare de caz, *Sibiul Medical*, vol.18, Nr.1, Ianuarie-martie 2007
23. Bratu D., A.Sabău, D.Sabău, A.Dumitra, D.Belean, A.Coman- „Chirurgia laparoscopică versus chirurgia clasică în tratamentul chistului hidatic hepatic”-*Sibiul Medical*- vol 18, Nr.1, ianuarie-martie 2007, pag. 70.
24. Brătucu E, Ulmeanu D, Bota D, Mauru M - Optiuni terapeutice in chisturile hidatice centrale ale lobului hepatic drept, *Chirurgia (Bucuresti)*, 1995, vol. XLIV, 44(3): 29-41
25. Brunetti E, Gulizia R, Garlaschelli AL: Cystic echinococcosis of the liver associated with repeated international travels to endemic areas. *J Travel Med* 2005 Jul-Aug; 12(4): 225-8[Medline
26. Brunetti E, Troia G, Garlaschelli AL: Twenty years of percutaneous treatments for cystic echinococcosis: a preliminary assessment of their use and safety. *Parassitologia* 2004 Dec; 46(4): 367-70[Medline].
27. [Bulbuler N, Ilhan YS, Kirkil C, Yenicerioglu A, Ayten R, Cetinkaya Z](#). The results of surgical treatment for hepatic hydatid cysts in an endemic area *Turk J Gastroenterol*. 2006 Dec;17(4):273-8.
28. Burlui D., Roșca M. - Chirurgia chistului hidatic hepatic, Ed. Medicală, Bucuresti, 1977
29. [Busic Z, Lemac D, Stipancic I, Busic V, Cavka M, Martic K](#). Surgical treatment of liver echinococcosis--the role of laparoscopy *Acta Chir Belg*. 2006 Nov-Dec;106(6):688-91.

30. C. Mircioiu, G. Ionescu, Szabo, O. Pereni, I. Mihut, A.Cucu, Evoluția tratamentului chirurgical al chistului hidatic hepatic într-o statistică pe trei decenii: Al XVII-lea Congres Național de Chirurgie, Iași 23-27 mai 1993 p.116-117.
31. C. Smarandache, D. Căndea, E. Kulcsar, R. Elefterescu, A. Șanta, C. Marosin: Chistul hidatic la copil- Journal of Romanian Parasitology, vol.VI, nr.1-2; 1996
32. C.Manterola, O.Fernandez, S.Munoz, M.Vial, H.Losada, R.Carrasco, N.Bello, N.Barroso-„Laparoscopic pericystectomy for liver hydatid cysts”-Surgical Endoscopy vol16, Number 3/March, 2002
33. Chang Z.F., Huang T.L., Chen C.L., Lee T.V.- Variation of the intrehepatic bile ducts: aplicacion in living related hepatic transplantation and splitting liver transplantation. Clin. Transplantation 1997; 11: 337-340.
34. [Chen W, Xusheng L.](#) Laparoscopic surgical techniques in patients with hepatic hydatid cyst. Am J Surg. 2007 Aug;194(2):243-7.
35. Chira R, Mircea PA, Șuteu M, Vălean Simona, Onea Diana, Kerekes Tunde, Olinic N. Hematom hepatic post-traumatic abcedat tratat prin drenaj percutan ecoghidat, Revista română de ultrasonografie, 1999, vol. 1, nr. 2
36. Cirenei A, Bertoldi I: Evolution of surgery for liver hydatidosis from 1950 to today: analysis of a personal experience. World J Surg 2001 Jan; 25(1): 87-92[Medline].
37. Costache M. -Omul-Perfecțiune și Perfectibilitate, esențial de biologie umană aplicată-Ed. Universității Lucian Blaga-Sibiu 1999.
38. Costache M.,Seres Sturm L.,-Anatomia omului vol.IV.Ed. Univ. Lucian Blaga Sibiu-2001
39. Crippa FG, Bruno R, Bruneti E, Filice C - Echinococcal liver cysts: treatment with eco-guided percutaneous puncture PAIR for echinococcal liver cysts, Ital J Gastroenterol Hepatol. 1999 Dec; 31 (9):884-92
40. Crump J.A, Murdoch D.R, Baker M.G: Emerging Infectious Diseases in an Island Ecosystem: The New Zealand Perspective, Emerging Infectious Diseases, September-October 2001,7,5, 767-772.
41. Cucu Alin, Mircea Petru Adrian, Pop Sorin, Chira Romeo, Vălean Simona:„Ultrasonografia chistului hidatic hepatic-mai multe fețe ale aceleiași afecțiuni”-Revista de Ultrasonografie nr.2/2000
42. Deve F. L’echinococose secondaire, mairo et cie, 1946
43. Diez J, Decoud J, Gutierrez L, et al: Laparoscopic treatment of symptomatic cysts of the liver. Br J Surg 1998 Jan; 85(1): 25-7[Medline].
44. Dudea S. Identificarea segmentelor hepatice prin ecografie, Revista română de ultrasonografie, 1999, vol. 1, nr. 2, pag. 75.
45. Dziri C, Haouet K, Fingerhut A: Treatment of hydatid cyst of the liver: where is the evidence? World J Surg 2004 Aug; 28(8): 731-6[Medline].
46. Eckert J, Deplazes P: Biological, epidemiological, and clinical aspects of echinococcosis, a zoonosis of increasing concern. Clin Microbiol Rev 2004 Jan; 17(1): 107-35[Medline].
47. Ehrhardt AR, Reuter S, Buck AK, Haenle MM, Mason RA, Gabelmann A, Kern P, Kratzer W. Assessment of disease activity in alveolar echinococcosis: a comparison of contrast- enhanced ultrasound, three-phase helical CT and [(18)F]fluorodeoxyglucose positron- emission tomography. Abdom Imaging. 2006 Dec 2; [Epub ahead of print]
48. Elefterescu R, Covalcic M, Sfrangeu S, Vaida M, „Bazele imagisticii medicale: utilizarea informaticii în domeniul medical”
49. Elefterescu R, Mihalache C. Aspecte anatomo-imagistice în Medicina Nucleară, Editura Universității "Lucian Blaga", 2000
50. Elefterescu R. Curs de ecografie, Ed. Universității "Lucian Blaga", Sibiu, 2001
51. Elefterescu R. *Radiologie*, vol. II, Ed. Universității "Lucian Blaga", Sibiu, 1997
52. Elsebaie SB, El-Sebae MM, Esmat ME: Modified endocystectomy versus pericystectomy in echinococcus granulosus liver cysts: a randomized controlled study, and the role of specific anti-hydatid IgG4 in detection of early recurrence. J Egypt Soc Parasitol 2006 Dec; 36(3): 993-1006[Medline].
53. F. Martmona, A. Cristian, A. Cucu, Chisto – perichistectomie ideală laparoscopică pentru chist hidatic hepatic unilocular, Congresul Național de Chirurgie Sinaia 2002, rezumat în volumul congresului.
54. Fabiani P, Iannelli A, Chevallier P, et al: Long-term outcome after laparoscopic fenestration of symptomatic simple cysts of the liver. Br J Surg 2005 May; 92(5): 596-7[Medline].
55. Fiamingo P, Tedeschi U, Veroux M, et al: Laparoscopic treatment of simple hepatic cysts and polycystic liver disease. Surg Endosc 2003 Apr; 17(4): 623-6[Medline].
56. Filippou D, Tselepis D, Filippou G: Advances in Liver Echinococcosis: Diagnosis and Treatment. Clin Gastroenterol Hepatol 2006 Dec 5;[Medline].
57. Flisser A: Larval cestodes. In: Collier L, Balows A, Sussman M, eds. Topley and Wilson's Microbiology and Microbial Infections. Parasitology. Vol 5. 9th ed. New York, NY: Oxford University Press; 1998: 539-60.

58. [Furcea L, Pop F, Iancu C, Bala O, Radu H, Graur F, Tomus C, Vlad L.](#) Laparoscopic surgery of hepatic hydatid cyst at the 3rd Surgical Clinic, Cluj-Napoca Chirurgia (Bucur). 2007 Jan-Feb;102(1):31-6. Romanian
59. G. Ionescu, P. Mircea, A. Cucu-Dynamics of residual cavity after hydatid cyst surgery: - British Journal of Surgery, EuroSurgery Bruxelles June 1992, p.62.
60. Galati G, Sterpetti AV, Caputo M, Adduci M, Lucandri G, Brozzetti S, Bolognese A, Cavallaro A. Endoscopic retrograde cholangiography for intrabiliary rupture of hydatid cyst. Am J Surg. 2006 Feb;191(2):206-10.
61. Garcia H.H, Moro P.L, Schantz P.M, Zoonotic helminth infections of humans: Echinococcosis, cysticercosis and fascioliasis. Curr. Opin Infect. Dis. 2007, oct; 20 (5): 489-494.
62. Gherman I, sub redacția - Boala hidatică Ed. Medicală, București, 1991
63. Goldberg B, Pettersson H. Ultrasonography, 1996, The Nicer Year Book
64. Goldsmith N.A, Woodburne R.T-„Surgical anatomy pertaining to liver resection. Surgery, Gynecology and Obstetrics, 195:310-318, 1957
65. Hansen P, Bhojryal S, Legha P, et al: Laparoscopic Treatment of Liver Cysts. J Gastrointest Surg 1997 Jan; 1(1): 53-47[[Medline](#)].
66. Henry Gray ( Editor ), et al/ 1995- Gray`s Anatomy: The Anatomical Basis of Medicineand Surgery
67. Hiatt J.R., Gabbaay J., Busuttill R.W.- Surgical anatomy of the hepatic arteries in 1000 cases. Ann. Surg. 1994; 220: 50-52
68. Hosseini SV, Ghanbarzadeh K, Barzin J: In vitro protoscolicidal effects of hypertonic glucose on protoscolices of hydatid cyst. Korean J Parasitol 2006 Sep; 44(3): 239-42[[Medline](#)].
69. Hosseini SV, Ghanbarzadeh K, Barzin J: In vitro protoscolicidal effects of hypertonic glucose on protoscolices of hydatid cyst. Korean J Parasitol 2006 Sep; 44(3): 239-42[[Medline](#)].
70. Houin R: Current Situation of Echinococcosis in Europe. Symposium on Environmental Adaptation of Echinococcus. Sapporo, Hokkaido, Japan, August 18-20, 1998.
71. Ionescu V, Nicolae Ș.,„Orientări în programul național de supraveghere, diagnostic și combatere a parazitozoonozelor în România”- Revista română de parazitologie, iunie 1995,V,1: 38-39.
72. Irinel Popescu ( sub redacția )-„Chirurgia ficatului” vol.I, Editura Universitară „Carol Davila” București-2004
73. Juvara I, Rădulescu D, Prișcu A :„Probleme medico-chirurgicale de patologie hepato-biliară, Ed. Medicală, București, 1969, 153-240.
74. Karaoglanoglu M, Akinci OF, Bozkurt S, et al. Effect of different pharmacologic and chemical agents on the integrity of hydatid cyst membranes. AJR Am J Roentgenol. 2004;183(2):465-469.
75. Katkhouda N, Hurwitz M, Gugenheim J, et al: Laparoscopic management of benign solid and cystic lesions of the liver. Ann Surg 1999 Apr; 229(4): 460-6[[Medline](#)].
76. Khoury G, Abiad F, Geagea T, et al: Laparoscopic treatment of hydatid cysts of the liver and spleen. Surg Endosc 2000 Mar; 14(3): 243-5[[Medline](#)].
77. Khoury G, Jabbour-Khoury S, Soueidi A, et al: Anaphylactic shock complicating laparoscopic treatment of hydatid cysts of the liver. Surg Endosc 1998 May; 12(5): 452-4[[Medline](#)].
78. Koroglu M, Akhan O, Gelen MT, Koroglu BK, Yildiz H, Kerman G, Oyar O. Complete resolution of an alveolar echinococcosis liver lesion following percutaneous treatment. Cardiovasc Intervent Radiol. 2006 May-Jun;29(3):473-8.
79. Koulas SG, Sakellariou A, Betzios J, Nikas K, Zikos N, Pappas-Gogos G, Tsimoyiannis EC. A 15-year experience (1988-2003) in the management of liver hydatidosis in northwestern Greece. Int Surg. 2006 Mar-Apr;91(2):112-6.
80. Lafortune M, Denys A, Sauvaet A, Schmidt S. Anatomy of the liver: what you need to know J Radiol. 2007 Jul-Aug;88(7-8):1020-35. French.
81. Lahmar S, Chehida FB, Petavy AF, Hammou A, Lahmar J, Ghannay A, Gharbi HA, Sarciron ME. Ultrasonographic screening for cystic
82. [Li F, Yang M, Li B, Yan L, Zen Y, Wen T, Zao J.](#) Initial clinical results of orthotopic liver transplantation for hepatic alveolar echinococcosis. Liver Transpl. 2007 Jun;13(6):924-6.
83. Lippincot Williams&Wilkis. Atlas of Anatomy, 1<sup>st</sup> edition, 2008
84. Liu-YH, Wang-XG, Chen-YT: Preliminary observation of continuous albendazole therapy in alveolar echinococcosis. Chin-Med-J-Engl. 1991, Nov 104 (11):930-3.
85. [Logar J, Soba B, Lejko-Zupanc T, Kotar T.](#) Human alveolar echinococcosis in Slovenia. Clin Microbiol Infect. 2007 May;13(5):544-6. Epub 2007 Mar 19.

86. Lupașcu Gh, Panaitescu D: Hidatidoza, Ed. Academiei Republicii Socialiste România, București, 1968, 49-64.
87. M Baharsefat, J Massoud, I Mobedi, A Farahnak, MB Rokni Seroepidemiology of Human Hydatidosis in Golestan Province, Iran Iranian J Parasitol: Vol.2, No.2, 2007, pp. 20-24
88. M.-T. Tajdine, A. Achour, M. Lamarni, M. Daali . Problèmes thérapeutiques du kyste hydatique du dôme du foie : à propos de 70 observations. Medecine et Armees T 34, nr. 3 juin 2006
89. Marks J, Mouiel J, Katkhouda N. et al : Laparoscopic liver surgery. A report on 28 patients. Surg. Endosc. 12: 331-334, 1998
90. [Mata-Miranda P, Osnaya-Palma I, Rodriguez-Prado U, Gutierrez-Marin A, Tawil M, Hernandez-Gonzalez S, Solano-Ceh M, Villalvaso L, Martinez-Maya JJ, Maravilla P, Garcia-de-la-Torre G, Flisser A](#): Epidemiologic and Ultrasonographic Study of Echinococcosis in a Community in the State of Mexico. Am J Trop Med Hyg. 2007 Sep;77(3):500-503.
91. [Mergen H, Genc H, Tavusbay C](#). Assessment of liver hydatid cyst cases--10 years experience in Turkey. Trop Doct. 2007 Jan;37(1):54-6.
92. Mircea PA, Chira R, Pop S, Vălean Simona, Cucu A. Ultrasonografia chistului hidatic hepatic. Revista română de ultrasonografie, 2000, vol. 2, nr. 3, pag. 155
93. Moncef Gargouri, Nejet Ben Amor, Ferid Ben Chehida, Azza Hammou, Hassen A. Gharbi, Mohamed Ben Cheikh, Hefdi Kchouk, Kamel Ayachi and Jean Yves Golvan: Percutaneous treatment of hydatid cystis ( Echnococcus Granulosus )- Cardiovascular and International Radiology, vol.13, nr. 3/may ,1990, pag. 169-173.
94. Moreno Gonzalez E, Meneu-Diaz JC, Moreno-Elola A. Echinococcal cysts: personal approach to the surgical treatment of echinococcal cysts. In: Baker RJ, Fischer JE, eds. Mastery of Surgery. 4th ed. Philadelphia, Pa: Lippincott Williams & Wilkins; 2001:1043-1045.
95. Morris Peter J, Wood W C. Oxford textbook of surgery, 2<sup>nd</sup> ed., 2001, Oxford University Press
96. Nakamura S., Tsuzuki T. - Surgical anatomy of the hepatic veins and the inferior vena cava. Surg. Gyn. Obst., 1981; 152: 43-50
97. Niculescu V., Matusz P., Motoc A., Roșu C., Niculescu M. - Variabilitatea morfologică a sistemului de ducte biliare intrahepatice, Al IX-lea Simpozion de Anatomie, Craiova, 29-30 aprilie, 1992, vol. Simpozion, p.100
98. Oancea T: Aspecte ale chirurgiei de graniță toracoabdominală, Ed. Militară București1983, cap. 10-11, p.142-159.
99. [Ozyer U, Kirbas I, Hasdogan B, Bozkurt A, Coskun M](#). Presentation of an unusual case of hepatic alveolar echinococcosis: multidetector CT and US findings Acta Gastroenterol Belg. 2007 Jan-Mar;70(1):34-5. No abstract available.
100. P. J, Kilinger, N. Godestatter, T. Schmid, E. Bodner, H.G. Schwelberger: Treatment of hepatic cysts in the era of laparoscopic surgery- British Journal of Surgery, vol. 84, issue 4 page 438- April 1997.
101. P. Mircea, A. Cucu, R. Vlaicu, Chist hidatic rupt și parțial evacuat în perichist. Aspecte ecografice de diagnostic și evoluție postoperatorie Al V-lea Congres Național de Gastroenterologie București 1986, p.373.
102. Palanivelu C.– Art of laparoscopic surgery, cap.48-Laparoscopic management of hydatid cyst of the liver, p.757-784, [Jaypee Medical Publishing](#), 2005
103. Palanivelu C., MCh, MNA, MS, Kalpesh Jani, MS, DNB, MNA, MS, Vijaykumar Malladi, MS, R. Senthilkumar, MS, P. S. Rajan, MS, K. Sendhilkumar, MS, R. Parthasarthi, MBBS, and Alfie Kavalakat, MS, DNB - Laparoscopic Management of Hepatic Hydatid Disease. JSLS. 2006 Jan–Mar; 10(1): 56–62.
104. Pană Mihaela, I. Popescu. Regenerarea hepatică în Chirurgia ficatului ( sub redacția I. Popescu) Ed. Universitară Carol Davila, București 2004, vol.I, p. 153-175
105. Papilian V.-Ficatul, în Anatomia omului, vol.II ed. VIII. Ed. BicAll, București 1998, 151-165.
106. Părăian I, Chistul hidatic hepatic, Ed. Didactică și Pedagogică, București, 1998, 11-12.
107. Pășcuț Magda. Curs de ecografie, Universitatea de Medicină și Farmacie "Victor Babeș", Timișoara, 2002
108. Popa F, Constantin V, Socea B, Moculescu C, Ciudin A, Popescu T: Obstrucția endogenă, cauză rară de ocluzie a intestinului sibțire, Chirurgia, număr special-rezumat, Al XXIII-lea Congres Național de Chirurgie, Băile Felix 24-27 mai 2006
109. Popa F, Gilorteanu H. -,Chirurgie”, vol I și II, Editura Național, 2000
110. Popescu I, Pietrăreanu D, Brașoveanu V: Considerații asupra tehnicii Couinaud de rezecție hepatică. Chirurgia ( Bucur ) 45:305-310, 1996
111. Popescu I-„Actualități în chirurgia ficatului”, Ed. Celsius, București, 1998, pag.177-192.
112. Popescu I. Tratat de patologie chirurgicală. Vol VIII și IX. Editura Academiei Române, 2009
113. Quenu J, Loygue J, Dubost Cl, Traite de technique chirurgicale, tome VII, Ed. Masson et Cie, Paris, 1959,9-13
114. Rădulescu Simona: Studiu clinic al eficienței tratamentului cu albendazol în hidatidoza umană, Chirurgia ( Buc.),1997,92,5,331-335.

115. Ratic R. E., Smith G.W., Anatomy and Physiology of the Liver in: Shackelford's Surgery of the Alimentary Tract, edited by G.D. Zuidema, Philadelphia, W.B. Saunders Co., 1991
116. Reuther G, Kiefer B, Tuchmann A, Pesendorfer FX. Pictorial essay. Imaging findings of pancreaticobiliary duct disease with single-shot MR cholangiopancreatography, American Journal of Roentgenology, 1997, no. 168, pag. 453
117. Robbins and Cotran Pathologic Basis of Disease, 7th Edition, p. 878
118. Rogan MT, Hai WY, Richardson R: Hydatid cysts: does every picture tell a story? Trends Parasitol 2006 Sep; 22(9): 431-8[Medline].
119. Romig T. Epidemiology of echinococcosis. Langenbecks Arch Surg. 2003;388(4):209-217.
120. Ronald Barbosa, Ahmed Mahmoud, Nathaniel Matolo, Sheela Kapre „Gigant Hydatid Cystic Liver Disease: A Challenging Problem for Western Surgeons-Surgical Rounds, Issue: May 2006.
121. Runge VM, Wells JW, Williams NN. Hepatic abscesses: magnetic resonance imaging finding using Gadolinium - BOPTA, Investigative Radiology, 1996, vol. 31, no. 12, pag. 781
122. S. M. Sadjjadi, S. Ardehali, B. Noman-Pour, V. Kemar and A. Izadpanah: Diagnosis of cystic echinococcosis: ultrasound imaging or countercurrent immunoelectrophoresis? Eastern Mediterranean Health Journal, vol 7, No. 6, nov. 2001, 907-911
123. Sabău D, Drăghințescu M, Iugulescu M, Avgherino S, Matei C, Stănicov O, Stoica T: „Chistul hidatic hepatic în chirurgia miniinvasivă”, Chirurgia, București, 1997, 92, 1, 59-65.
124. Sabău D, Șanta A, Bratu D, Antonescu M: „Diagnostic și tratament al chistului hidatic hepatic”, Acta Medica Transilvanica-2003
125. Sabău D., L.Cocora, O.Bardac, A.Șanta, D.Bratu, M.Antonescu: „Noțiuni actualizate de hidatologie”-Sibiul Medical-vol XIV-Nr.1, ianuarie-martie 2003, pag 12
126. Sabău D: Chistul hidatic hepatic, în Chirurgia ficatului ( sub redacția I. Popescu) Ed. Universitară Carol Davila, București 2004, vol.I, cap 13, pag.321-353
127. Sabău D: Dispozitiv pentru aspirația chistului hidatic hepatic sau a chistului de ovar. Buletinul oficial de proprietate industrială (București), nr. 8/2006
128. Sabău D: Dispozitivul pentru fragmentarea conținutului chistului hidatic. Buletinul oficial de proprietate industrială (București), nr. 8/2006
129. Sabău<sup>o</sup> A.D., D. Bratu<sup>o</sup>, A. Dumitra<sup>o</sup>, C. Luputiu<sup>o</sup>, A. Popentiu<sup>ooo</sup>, M. Antonescu<sup>o</sup>, F. Grosu<sup>oo</sup>, A. Șanta<sup>oo</sup>, A. Boicean<sup>oooo</sup>, M. Sava<sup>oooo</sup>, D. Sabău<sup>o</sup>. Abordul laparoscopic transpleurodiafragmatic al chistelor hepatice de dom posterior. Chirurgia (Bucur), 106, Nr. 4, Iulie-August 2011
130. Saeed I, Kapel C, Saida L.A, Willingham L, Nansen P: Epidemiology of Echinococcus granulosus in Arbil province, northern Iraq, 1990-1998, J. Helminthol 2000 Mar, 74(1):83-8.
131. Safioleas MC, Misiakos EP, Kouvaraki M, Stamatakos MK, Manti CP, Felekouras ES. Hydatid disease of the liver: a continuing surgical problem. Arch Surg. 2006 Nov;141(11):1101-8.
132. [Saidi F.](#) How to manage asymptomatic liver hydatids. Arch Iran Med. 2006 Apr;9(2):173-4. Review. No abstract available.
133. [Sakaguchi H, Tanaka T, Marugami N, Kichikawa K, Horiuchi H, Morioka C, Toyohara M, Moriya K, Nishiofuku M, Mitoro A, Fukui H, Hirai T, Yamashita N, Ouji Y, Ishizaka S, Yoshikawa M.](#) Cystic echinococcosis in immigrant from Peru: first case treated with percutaneous treatment in Japan. Parasitol Int. 2007 Sep;56(3):207-10. Epub 2007 Mar 1.
134. Șanta A., M. Munteanu: Tromboză arterială pulmonară cu chiste hidatice- Imagistica Medicală, nr.3, 1998.
135. Șanta A., M. Neamțu, C. Cazan, L. Dobrotă: Chistul hidatic la copil, aspecte epidemiologice, clinice și imagistice- Imagistica Medicală, nr.3, 1998.
136. Șanta A.: Prezentare de cazuri ecografice, Sibiul Medical, nr.1, ianuarie-martie 2000.
137. Seven R, Berber E, Mercan S, et al: Laparoscopic treatment of hepatic hydatid cysts. Surgery 2000 Jul; 128(1): 36-40[Medline].
138. [Shaw JM, Bornman PC, Krige JE.](#) Hydatid disease of the liver. S Afr J Surg. 2006 May;44(2):70-2, 74-7. Review.
139. Silva MA, Mirza DF, Bramhall SR, et al. Treatment of hydatid disease of the liver. Evaluation of a UK experience. Dig Surg. 2004;21(3): 227-233.

140. Slim Jouini, MD; Sarra Sehili, MD; Kamel Ayadi, MD Mohamad Suleyman, MS; Ronald Gourdie Eze Wachuku: Hepatic Hydatid Cyst With Fat-Fluid Level and Budd-Chiari Syndrome
141. Smego RA, Bhatti S, Khaliq AA, Beg MA: Percutaneous aspiration-injection-reaspiration drainage plus albendazole or mebendazole for hepatic cystic echinococcosis: a meta-analysis. *Clin Infect Dis* 2003 Oct 15; 37(8): 1073-83[Medline].
142. Spârchez Z, Fayyad E, Albu S, Tanțău M, Anton Ofelia, Grigorescu M, Badea R. Evaluarea ecografică a obstrucției biliare. Studiu retrospectiv
143. Sporea I, Popescu Alina, Dănilă Mirela, Șirli Roxana. Biopsia hepatică ecoghidată în diagnosticul hepatopatiilor cronice, *Revista română de ultrasonografie*, 2001, vol. 3, nr. 1, pag. 27
144. Tarcoveanu E, Georgescu S, Lupascu C, Bradea C, Crumpei F, Moldovanu R, Vasilescu A. Laparoscopic surgery of the liver. Discussions on 92 cases *Rev Med Chir Soc Med Nat Iasi*. 2006 Apr-Jun;110(2):334-46. Romanian.
145. Târcoveanu E., C. Bradea, R. Moldovanu G. Dimofte, Oana Epure Anatomia laparoscopică a ficatului și căilor biliare extrahepatice *Jurnalul de Chirurgie, Iasi*, 2005, Vol. 1, Nr. 1
146. Taylor BR, Langer B: Current surgical management of hepatic cyst disease. *Adv Surg* 1997; 31: 127-48[Medline].
147. Todorov T, Boeva V, Donev S: Risk Factors in the Spread of Cystic Echinococcosis. Symposium on Environmental Adaptation of Echinococcus. Sapporo, Hokkaido, Japan, August 18-20, 1998.
148. Triger D. R., -The liver as an immunology organ. *Gastroenterology*, 1976, 71:162
149. Vecchio R, Persi A, Lipari G, Polino C, Tomasi B, Vicari S, Alongi G, Puleo S. Laparoscopic treatment of liver hydatid cyst: personal technique *G Chir*. 2006 Apr;27(4):173-7. Review. Italian.
150. Vlad L: Chirurgie hepatică- aspecte actuale. Editura Casa Cărții de Știință, Cluj-Napoca, 1993.
151. Voiculescu B., Iliescu Cezar Angi. Anatomia ficatului în Chirurgia ficatului ( sub redacția I. Popescu) Ed. Universitară Carol Davila, București 2004, vol.I, p. 9-41
152. Vuitton D.A: The WHO Informal Working Group on Echinococcosis. Coordinating Board of the WHO-IWGE. *Parassitologia* 1997 Dec. 39: 349-53.
153. Watanabe Y, ato M, Ueda S. et al: Laparoscopic hepatic resection: a new safe procedure by abdominal wall lifting method. *Hepatogastroenterology* 44: 143-147, 1997.
154. Yagan R.J, Bani-Hani K.E, Heis H.A., The clinical and epidemiological features of hydatid disease in Northern Jordan” -*Saudi Medical Journal*.25(7):886-9,2004 Jul.
155. Yaghan R, Heis H, Bani-Hani K, et al. Is fear of anaphylactic shock discouraging surgeons from more widely adopting percutaneous and laparoscopic techniques in the treatment of liver hydatid cyst? *Am J Surg*. 2004;187(4):533-537.
156. Yorganci K, Sayek I. Surgical treatment of hydatid cysts of the liver in the era of percutaneous treatment. *Am J Surg*. 2002;184(1): 63-69.